Aortic Endografts
Issues for the Imager

Geoffrey D. Rubin, MD
University of Arizona

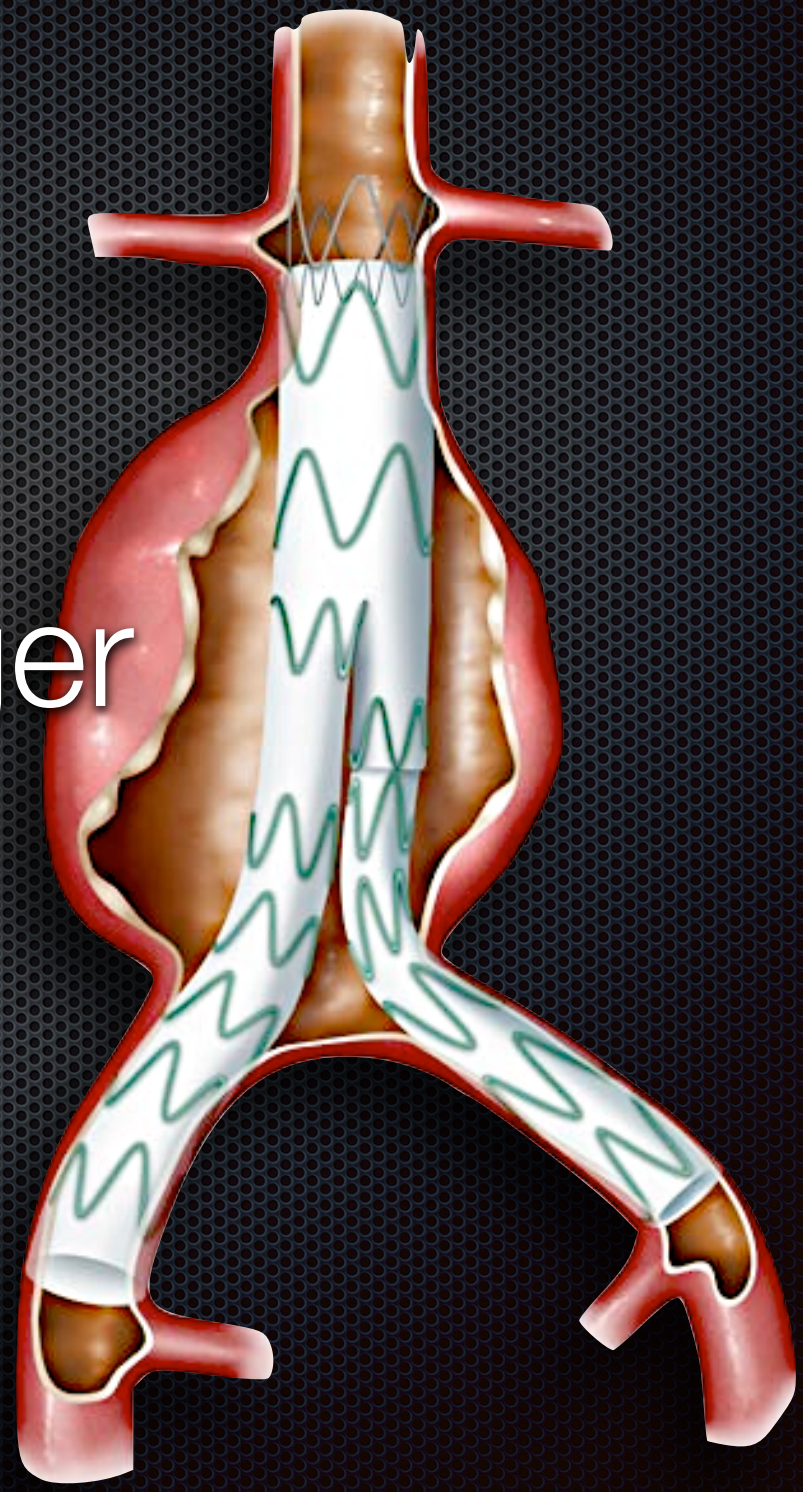

Acute Assessment

- Stent-graft patency
- Endoleak
- Branch occlusion
- Iliac dissection
- Hematoma
- Atheroembolism

Pulseless Leg

Post-Deployment Celiac Occlusion

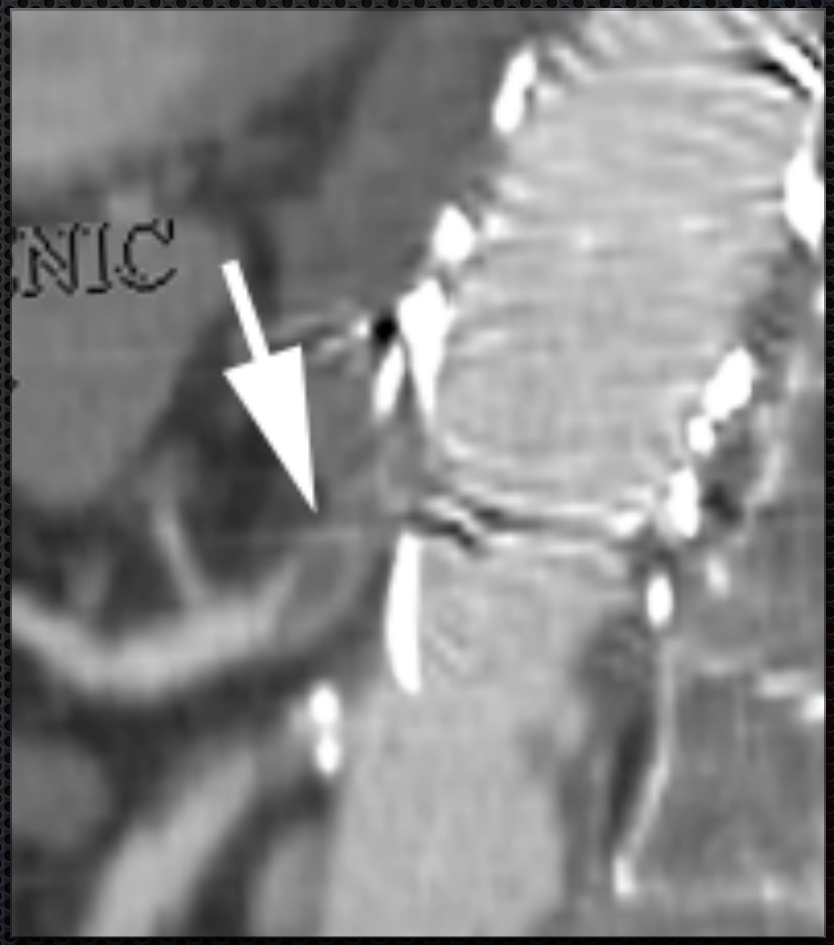

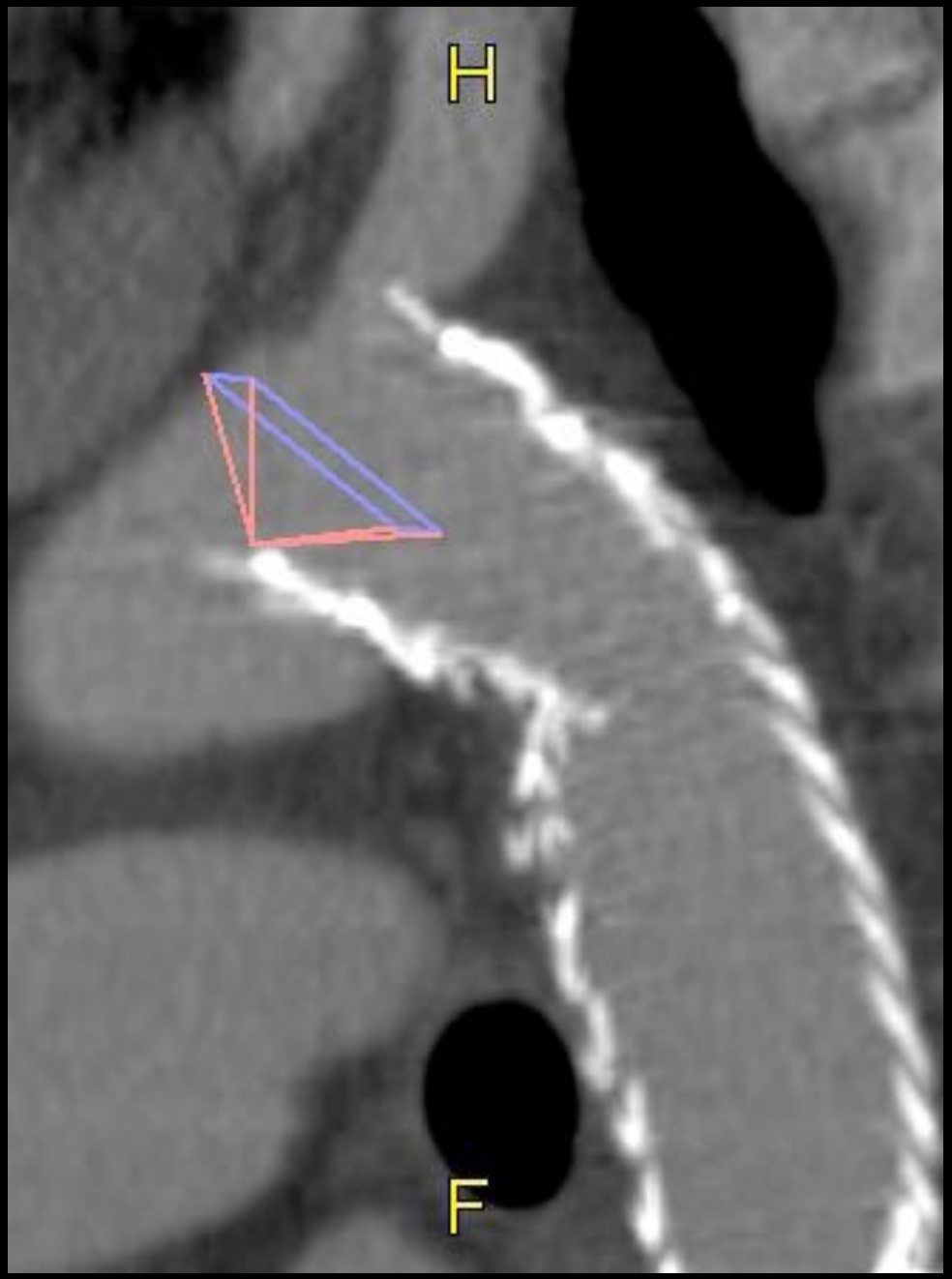
H
F

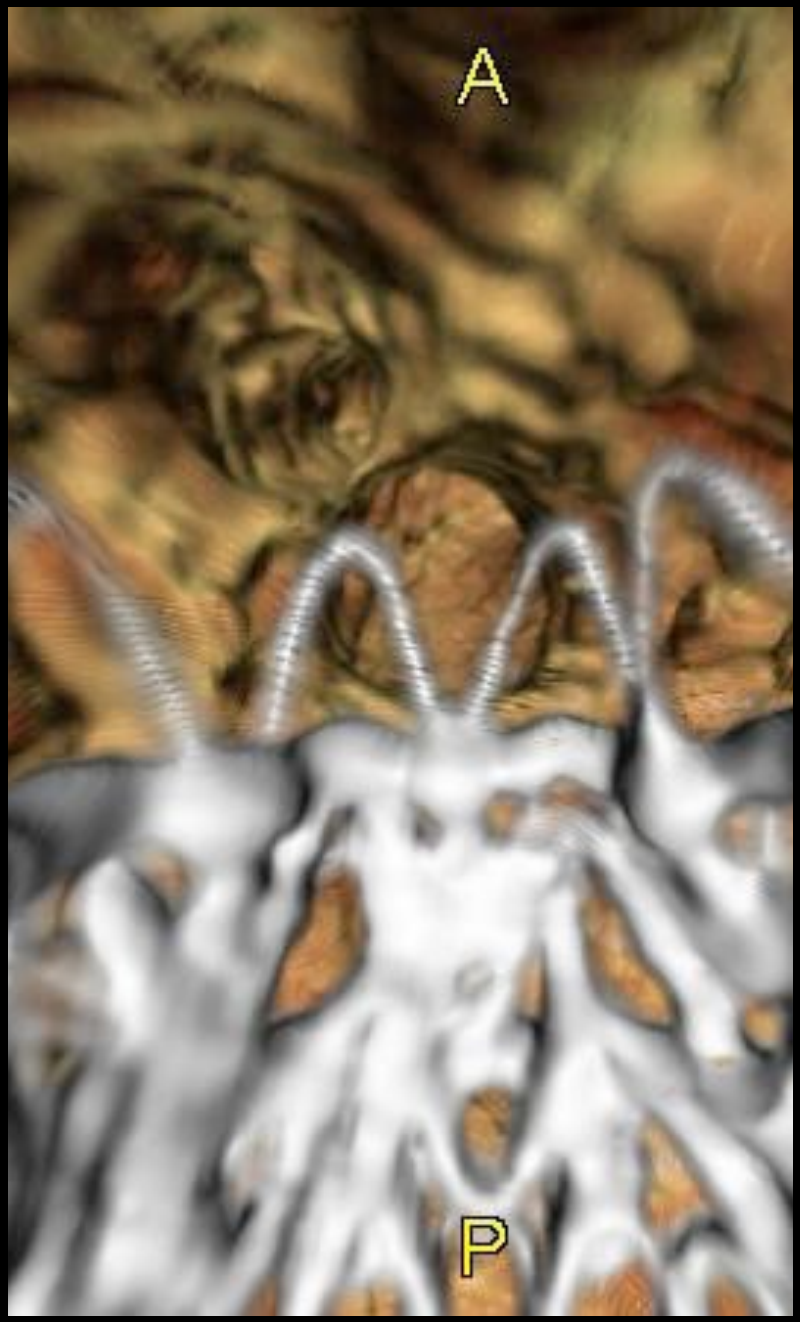
A
P

Incomplete expansion of distal limb

Risk of thrombosis or embolization

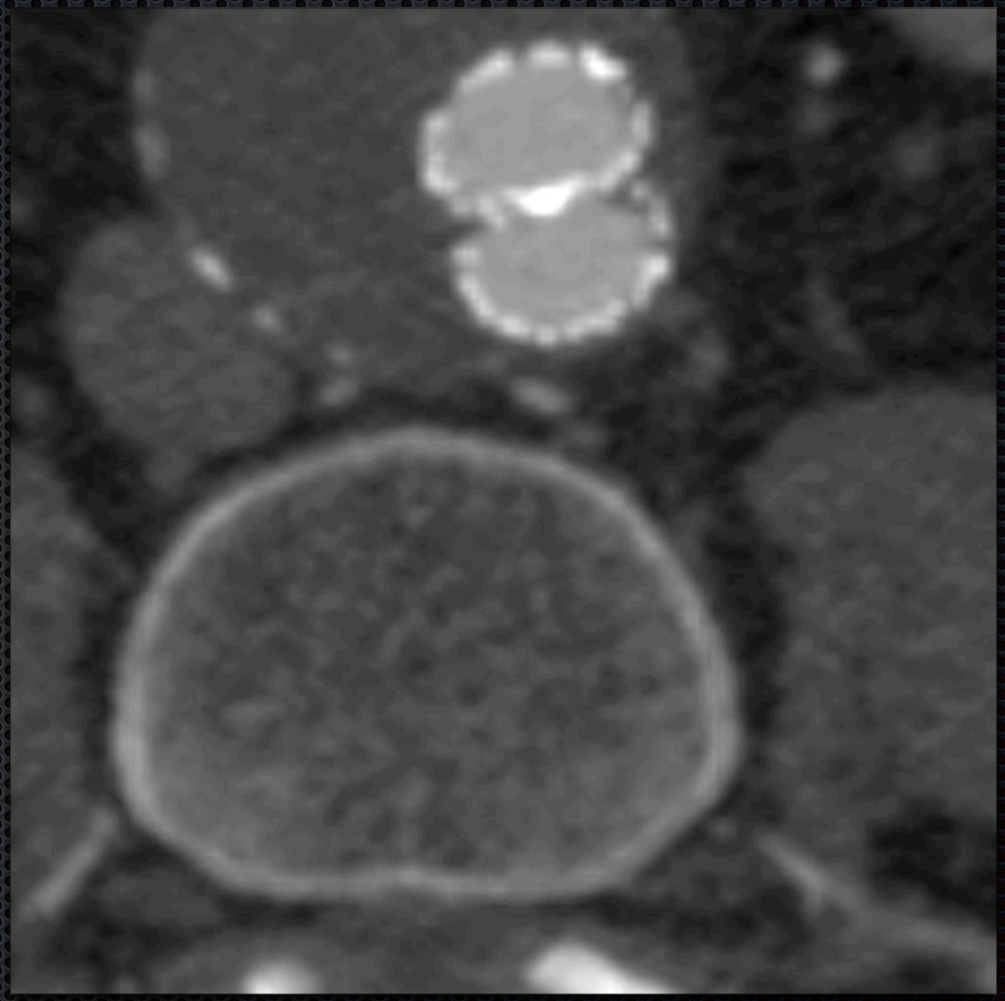

Incomplete expansion of distal limb

Risk of thrombosis or embolization

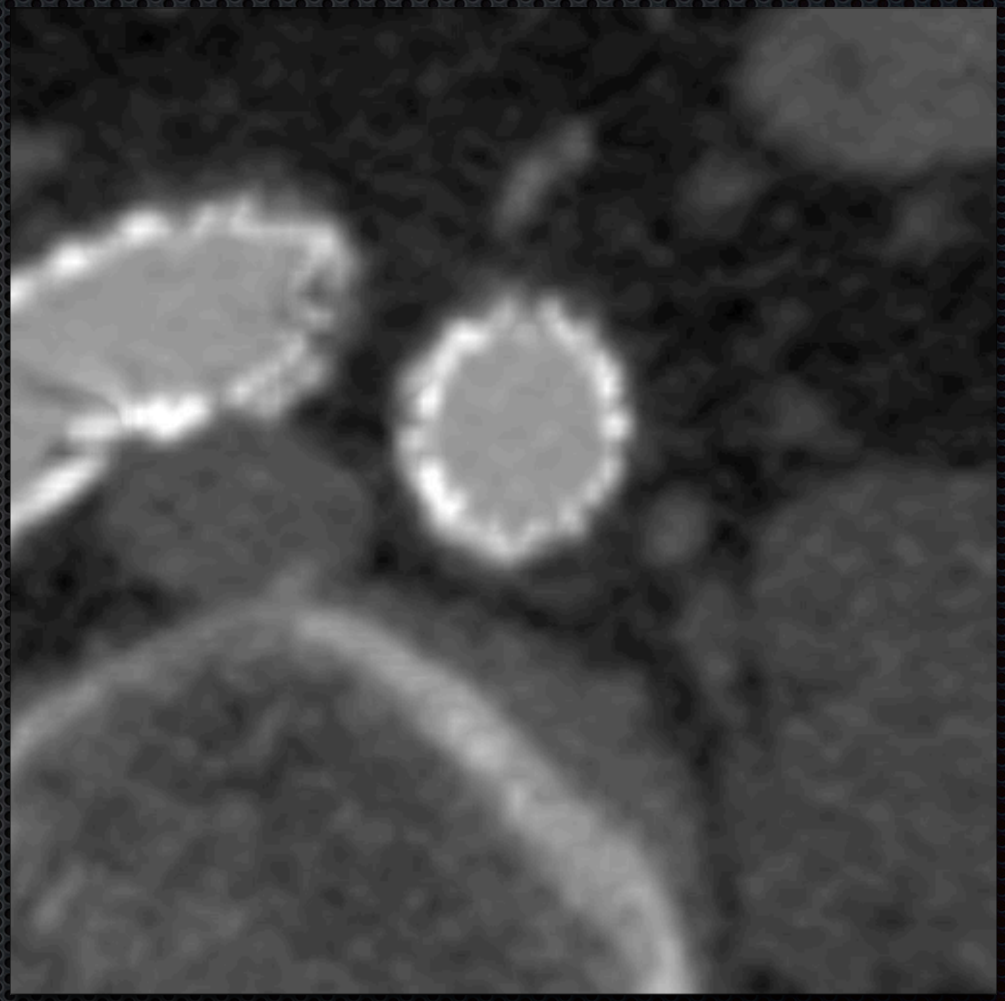

Oblique Reformation

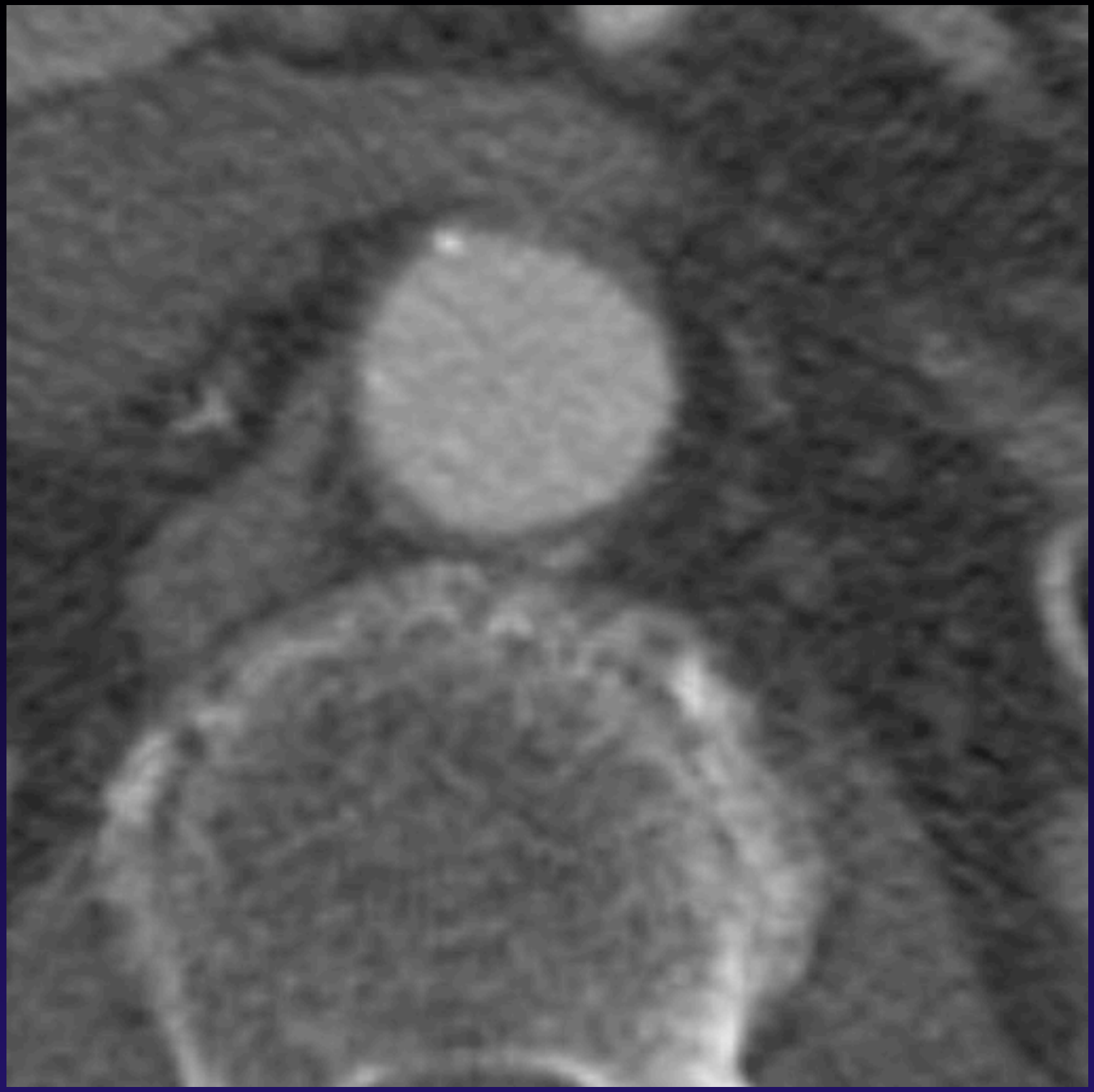

1 Day p̄ Bifurcated Aortic Stent-Graft

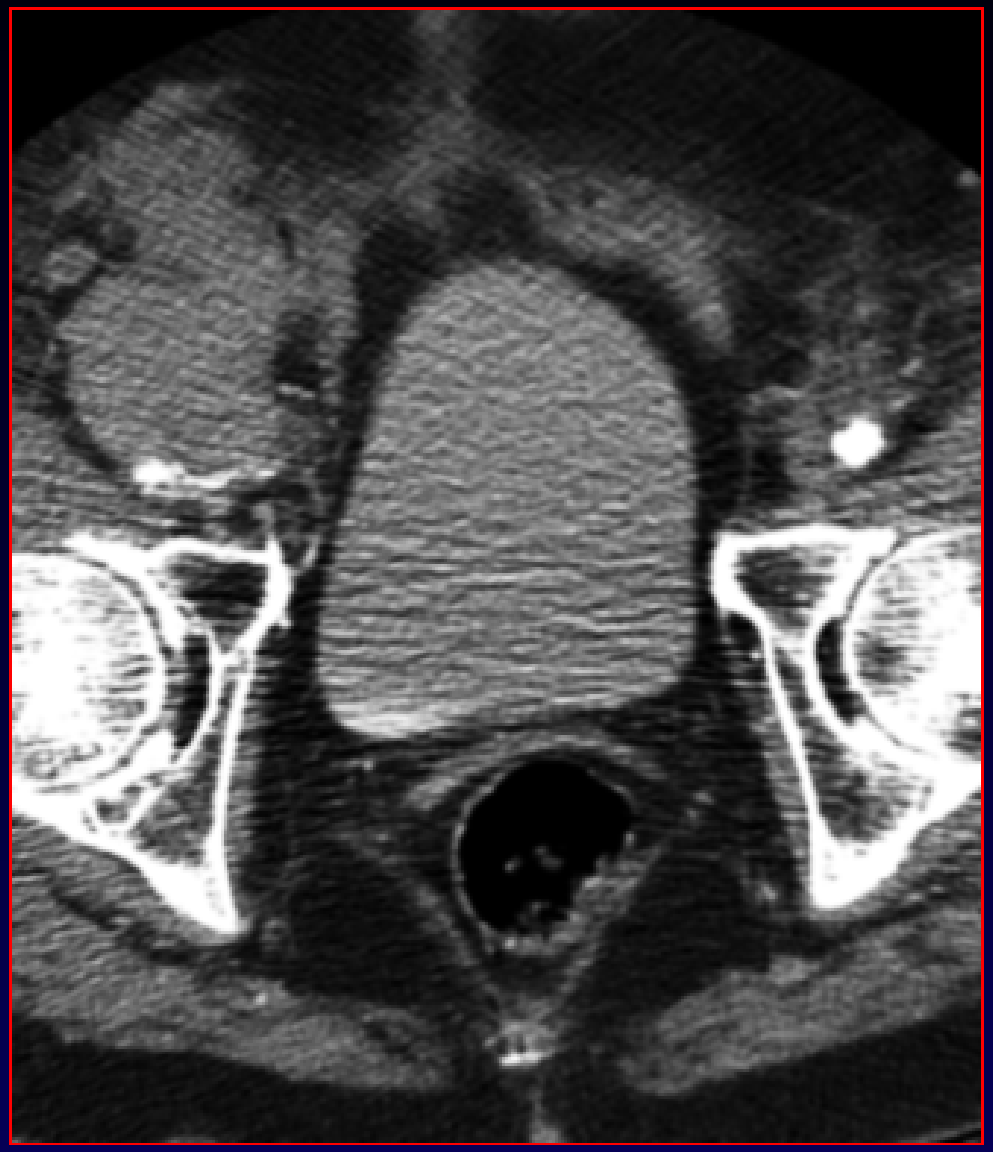

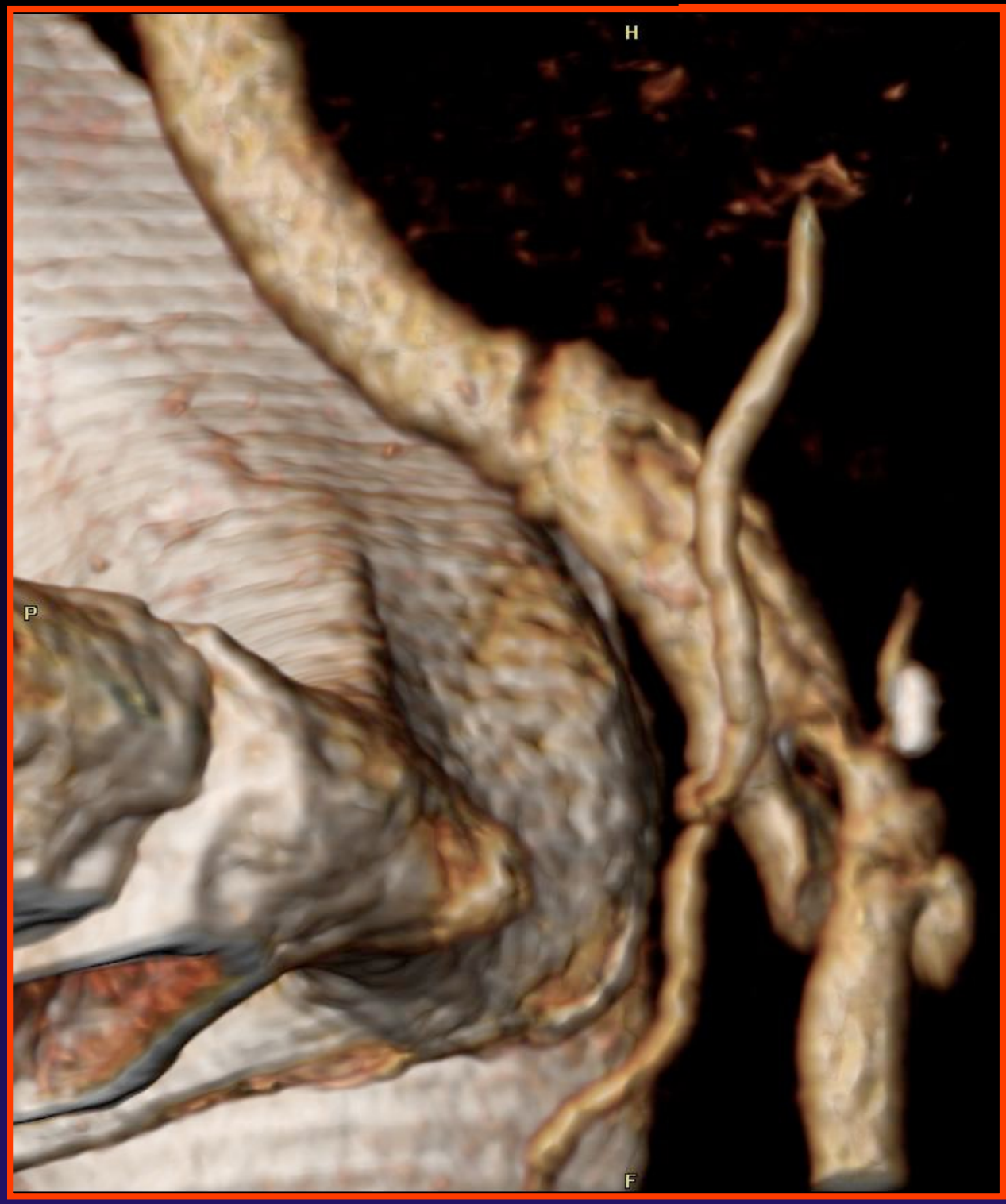
H
P
F


F

Renal Infarcts

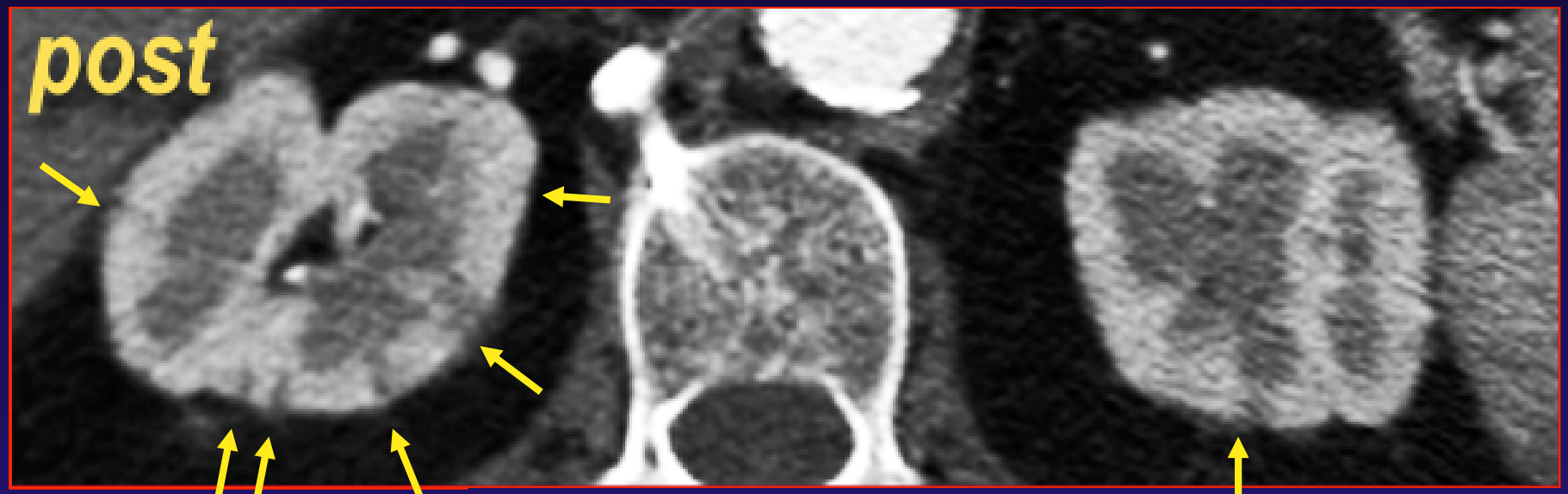

Thrombus in Urinary Bladder

Splenic Infarction

Endoleak

Endoleak

- CT considered reference standard
- 5 Types described

1: Attachment site

2: side branch (lumbar, IMA, access renal)

3: hole in graft or junction leak

4: transient trans-graft flow (not a leak)

5: endotension

Endoleak Classification

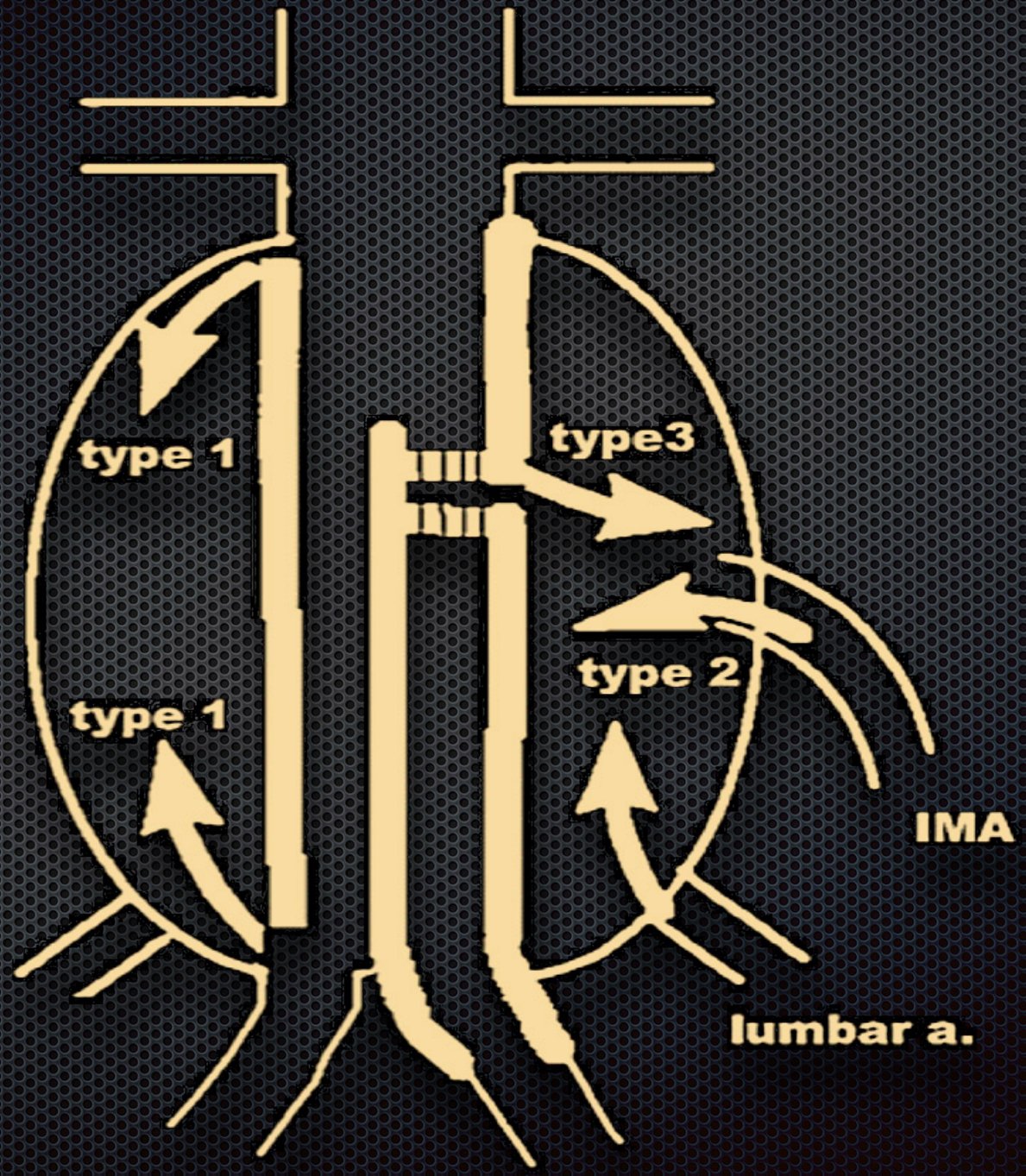

Endoleak via Patent IMA

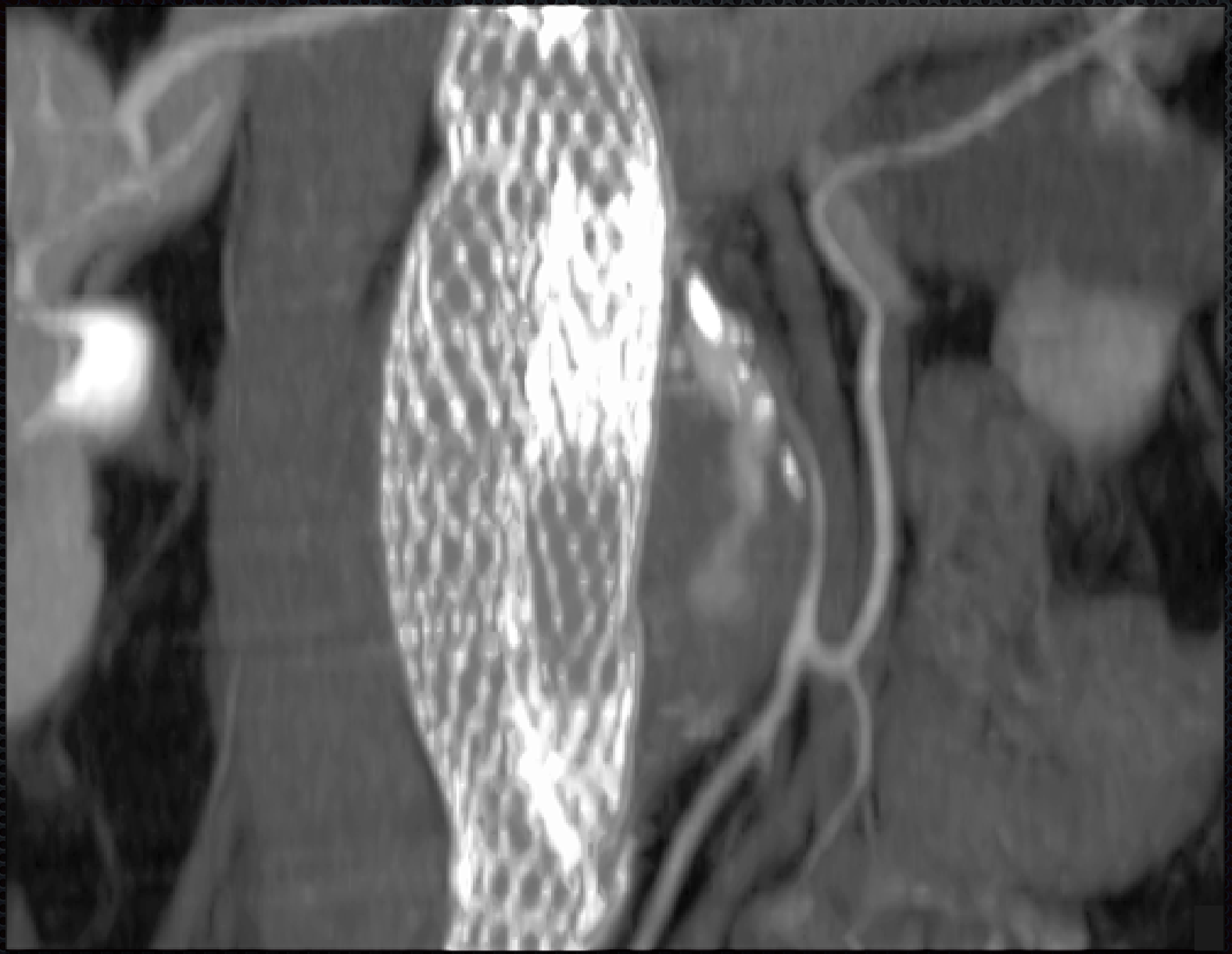

Triphasic CT Technique

- **73 patients post stent-graft**
- **33 endoleaks reviewed by 2 radiologists**

  30 (91%) detected on unenhanced/arterial phase

  32 (97%) detected on arterial/delayed phase

  33 detected on complete set of all 3 phases
- **20% of negative cases were "indeterminate" with biphasic technique**

Rozenblit, et al, Radiology 2003: 227;426

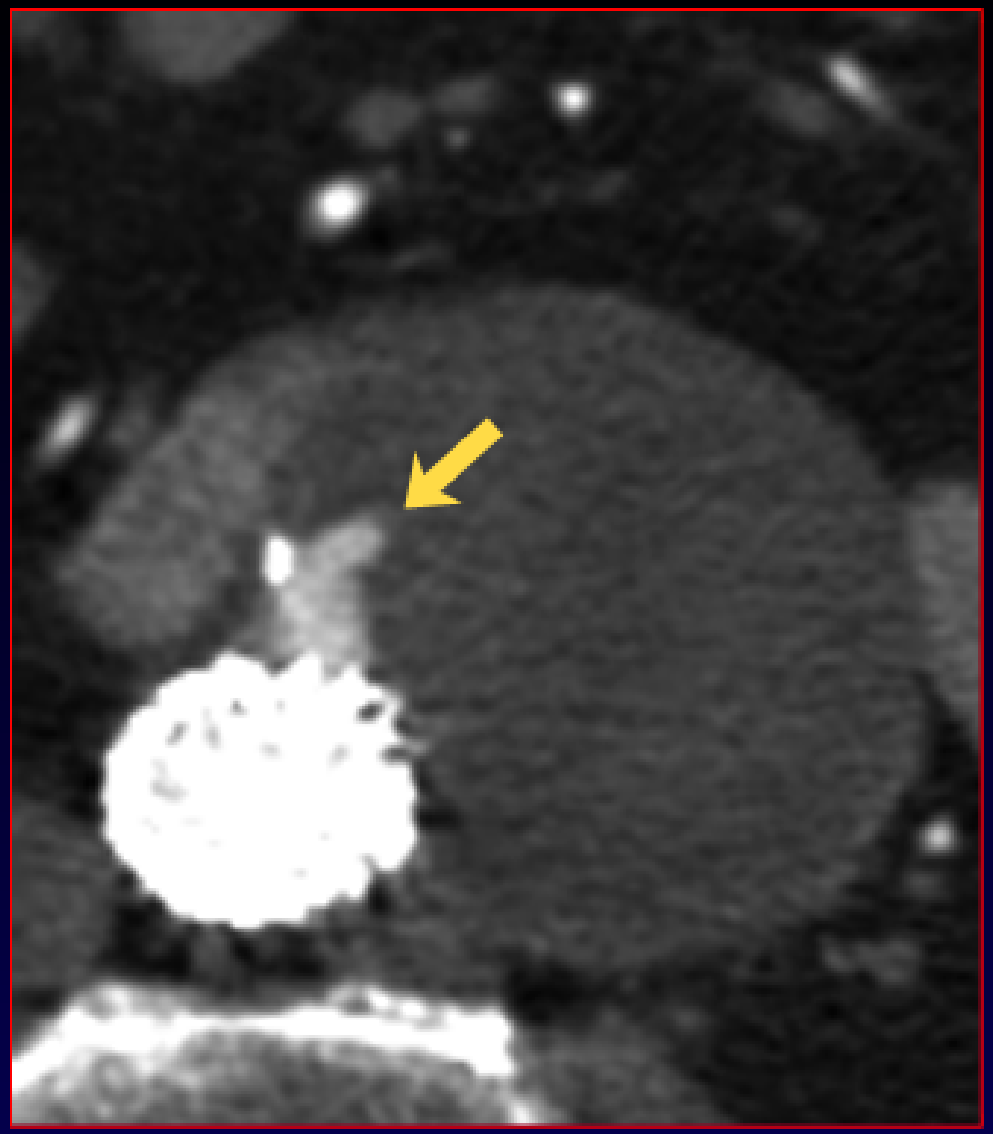

30 sec post inj.

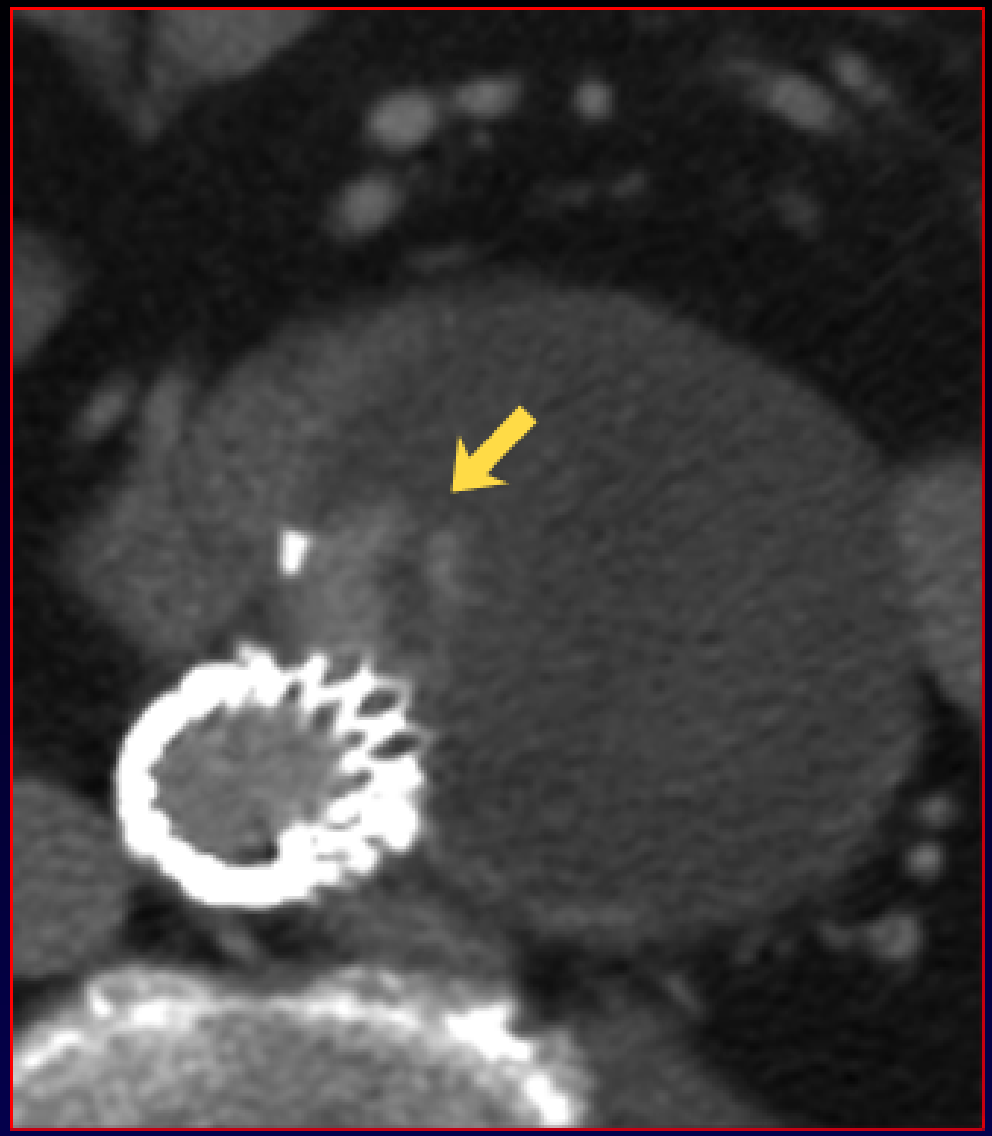

75 sec post inj.

28 sec p̄ Initiation of Contast

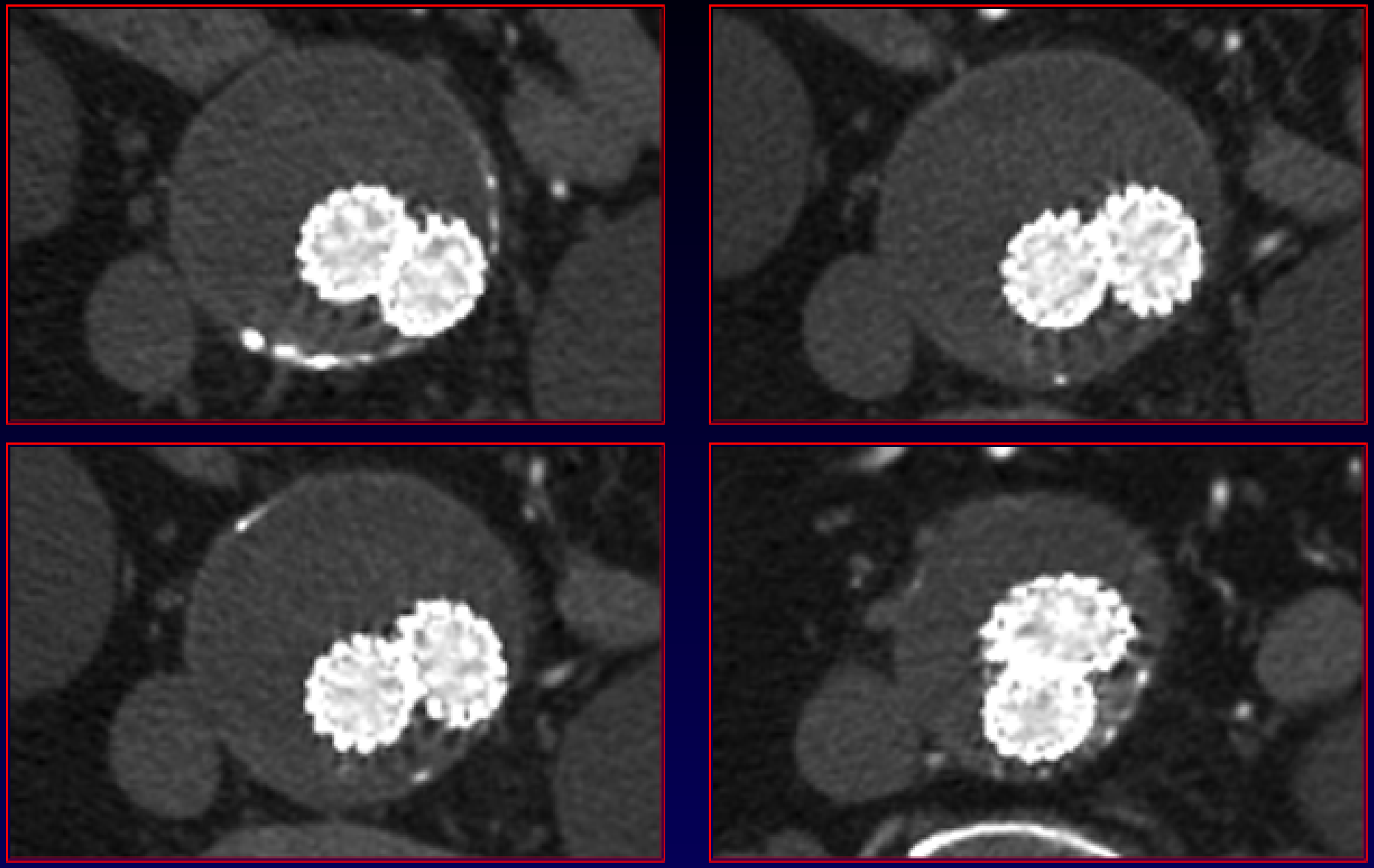

70 sec p̄ Initiation of Contast

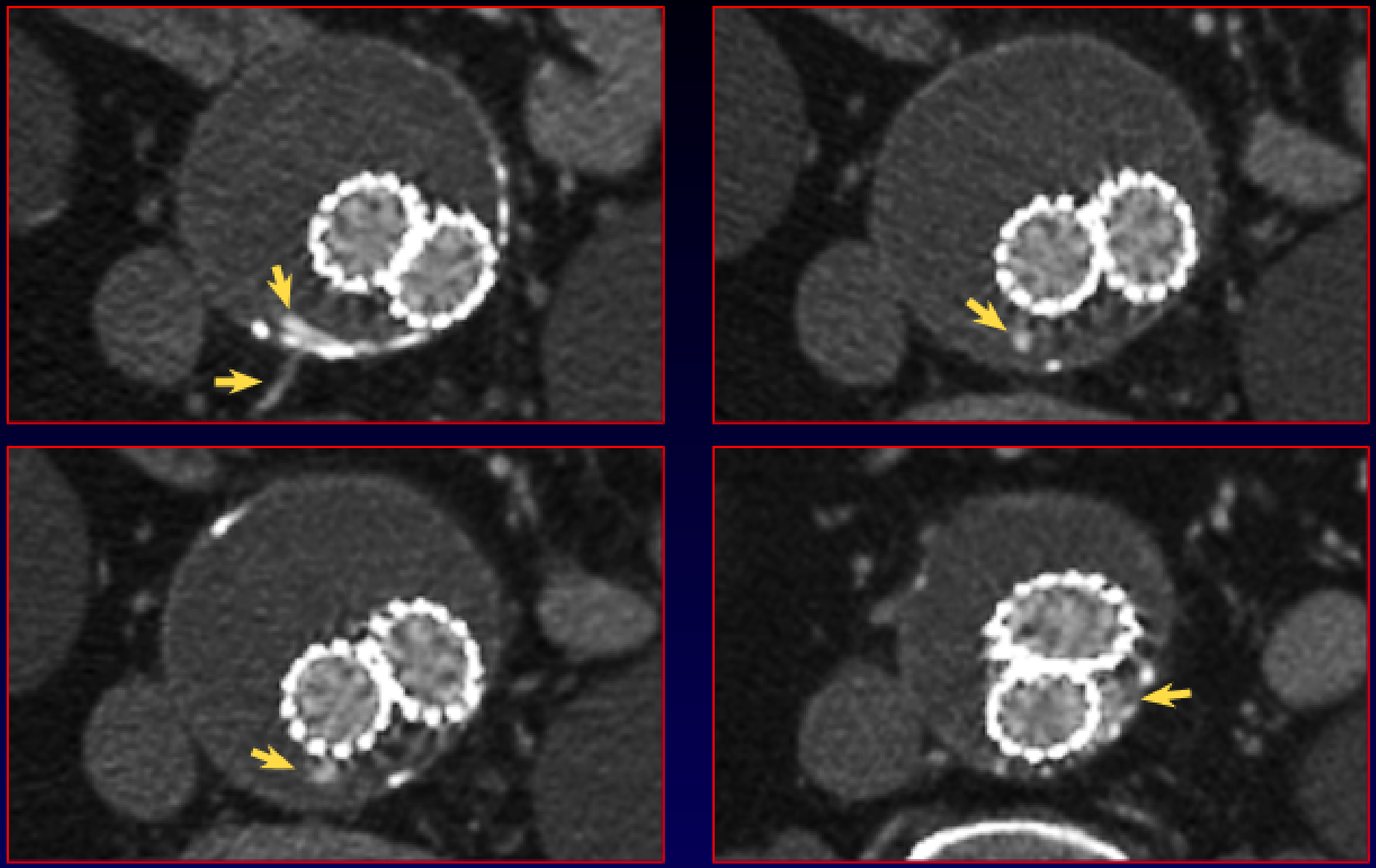

24 hrs. after Deployment

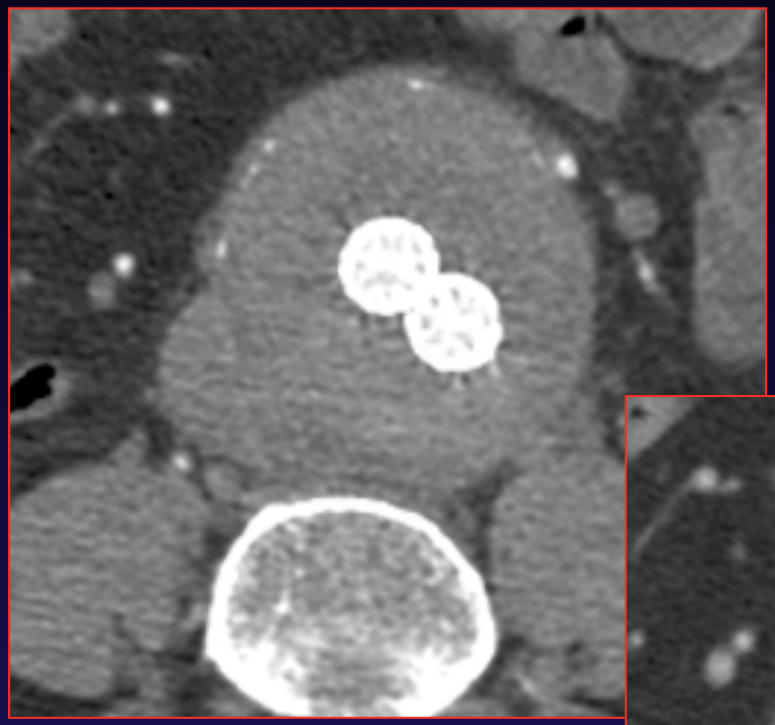

24 sec

100 sec

Pre-contrast

~~Endoleak~~

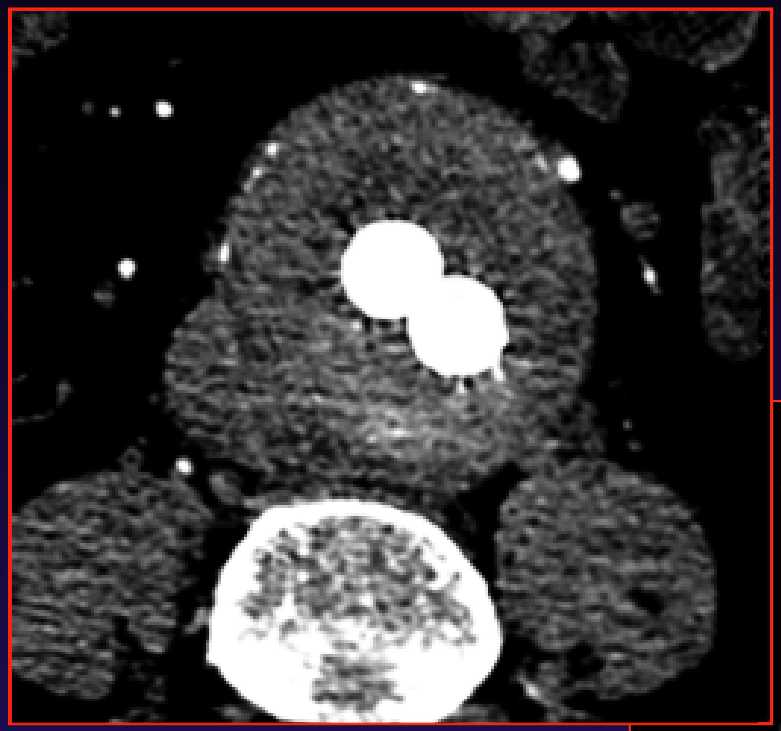

24 sec

100 sec

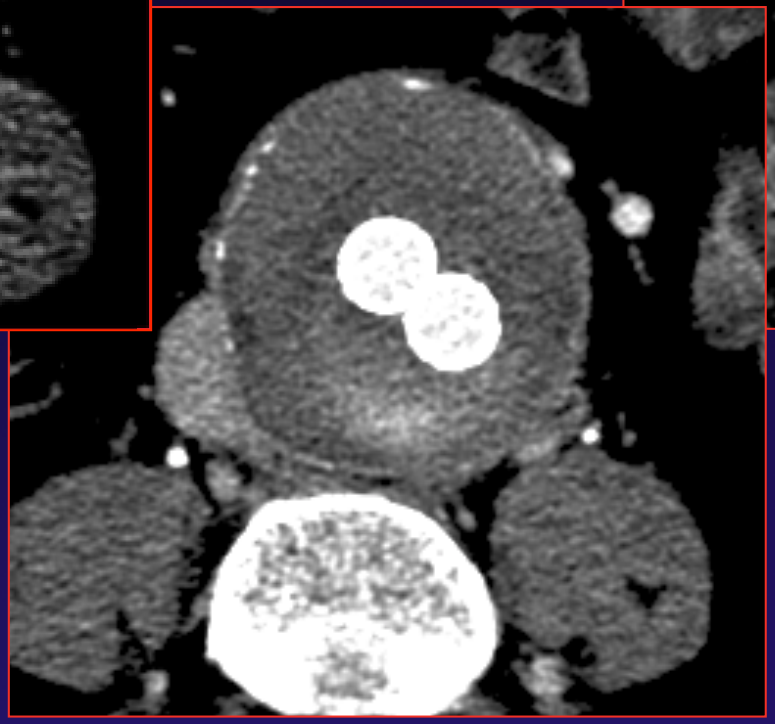

Pre-contrast

Endoleak

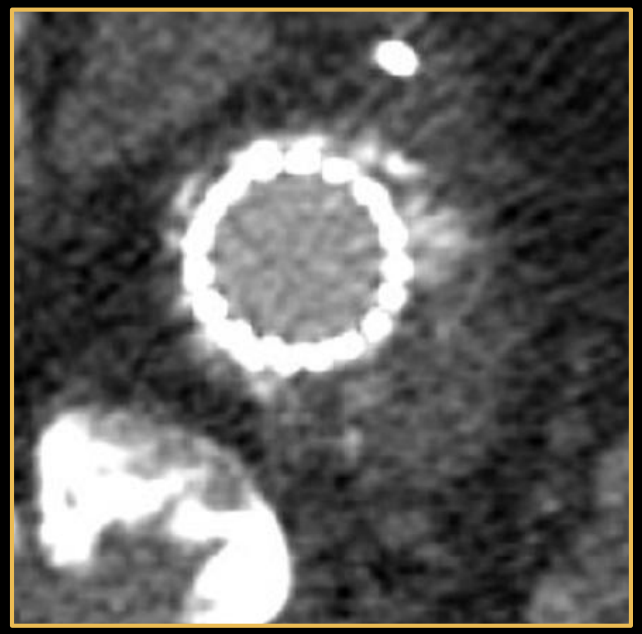

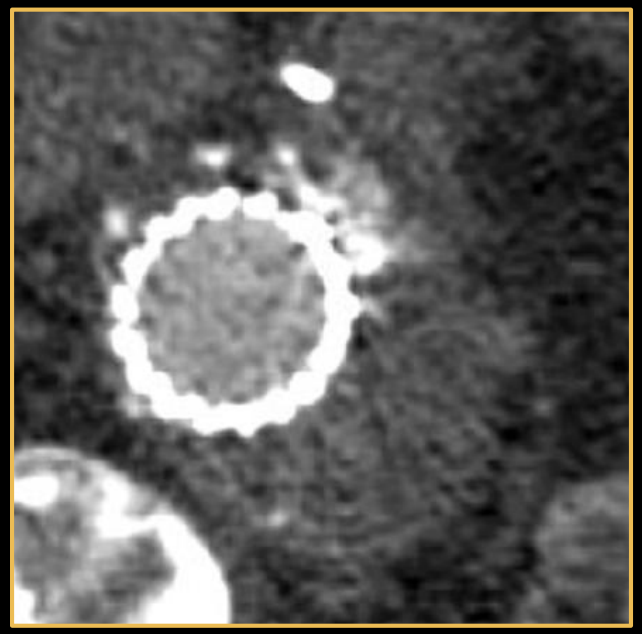

No Endoleak

Chronic Assessment

- Endoleak
- Stent-graft migration
- Stent-graft integrity
- Aortoiliac conformational changes
- Aneurysm size

3 wks pre

1 day post

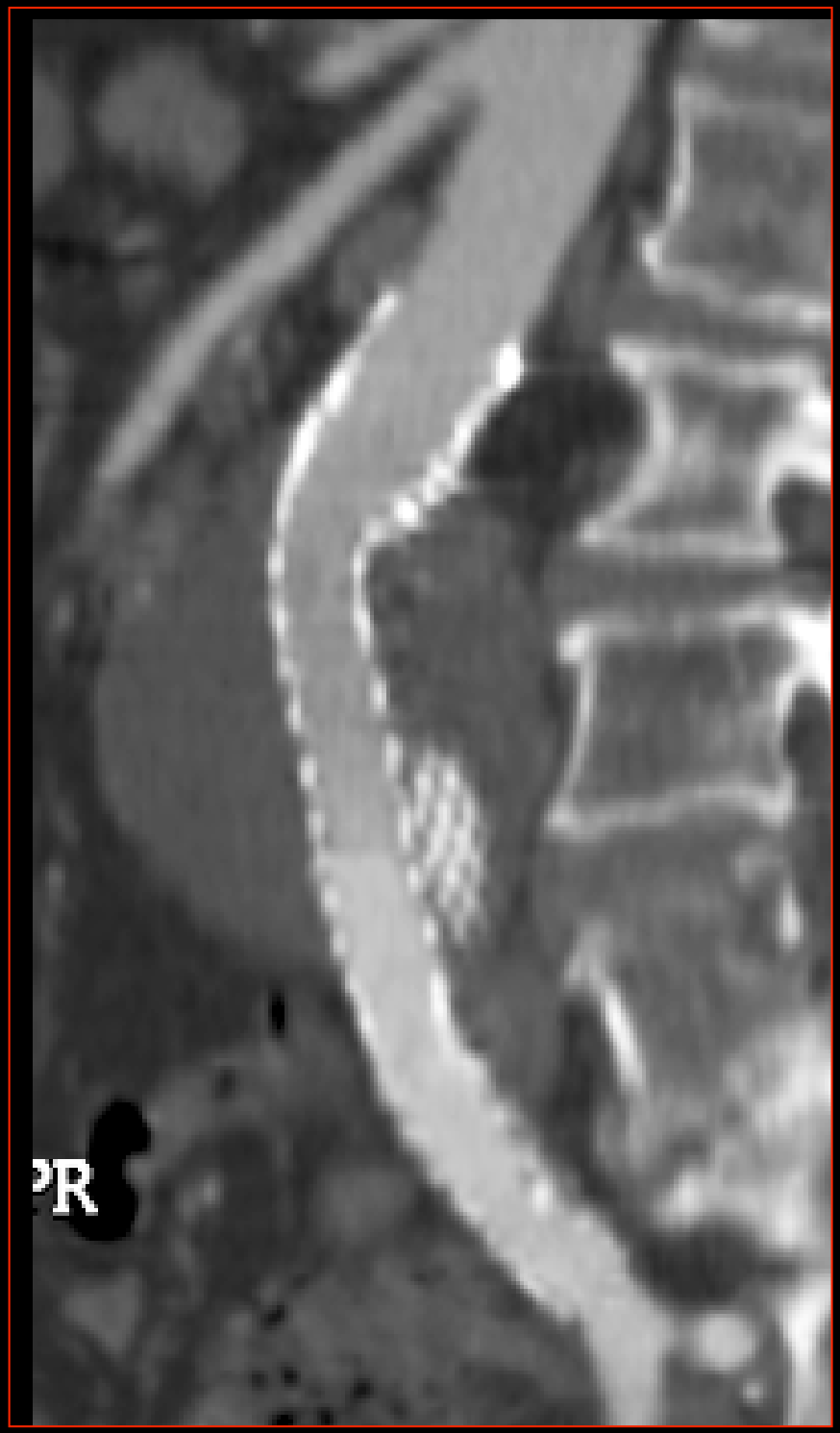

7 mos post

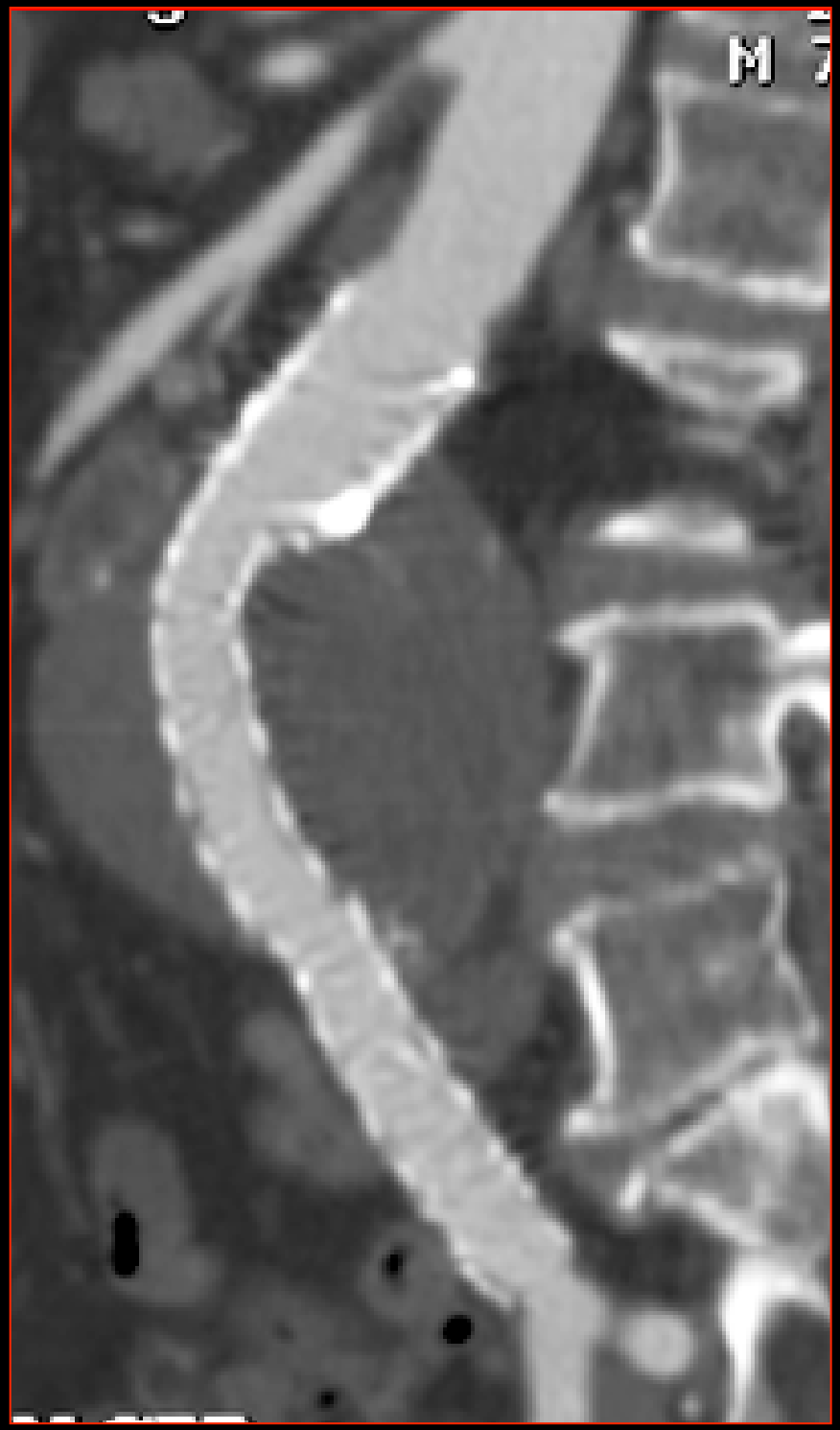

25 mos post

7 mos. post

25 mos. post

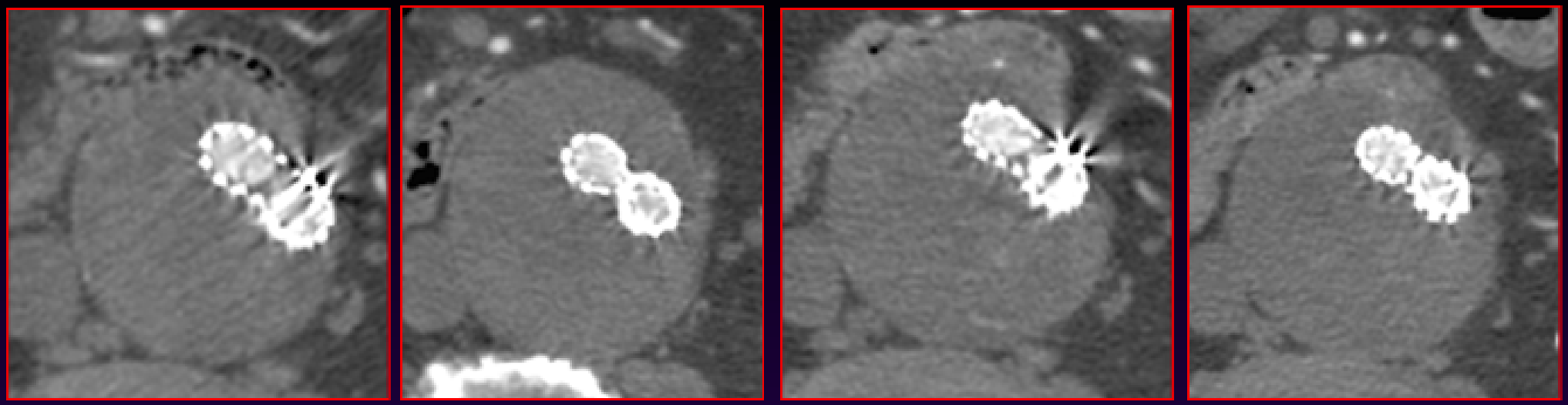

arterial phase (25 seconds)

7 mos. post

25 mos. post

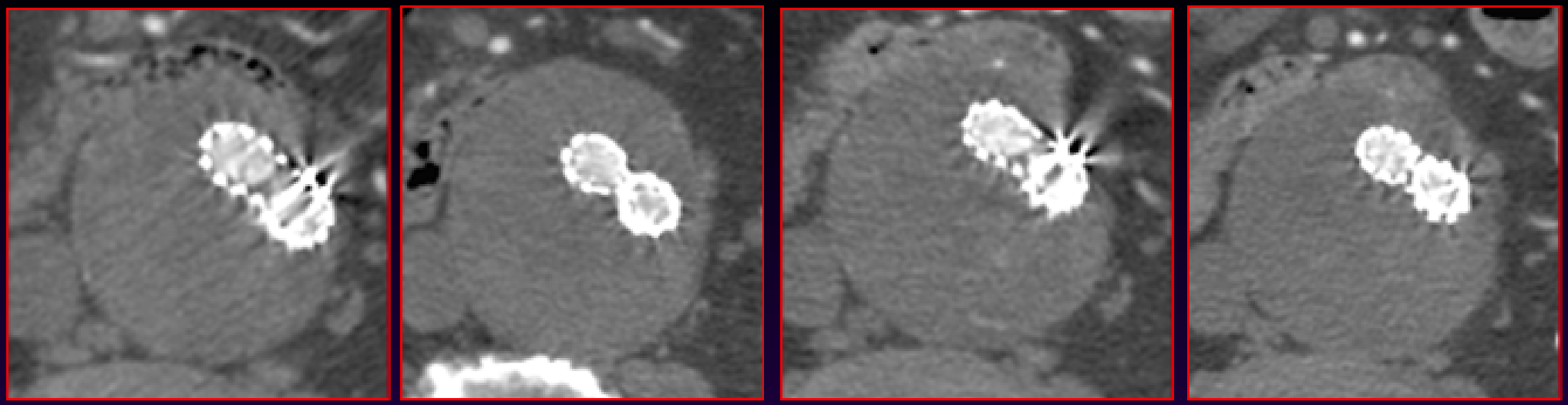

arterial phase (25 seconds)

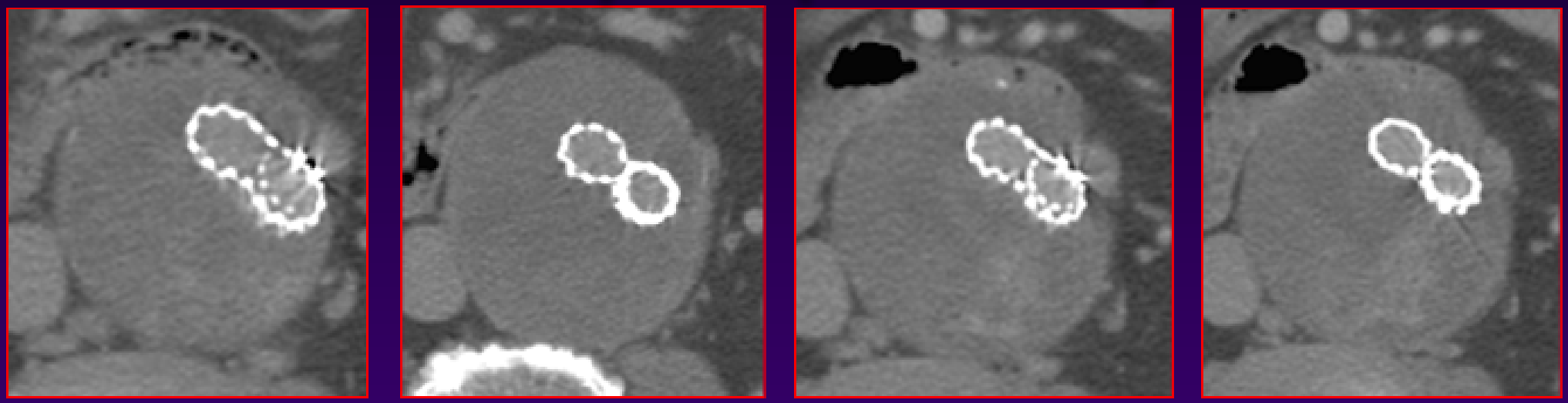

delay phase (75 seconds)

7 mos. post

25 mos. post

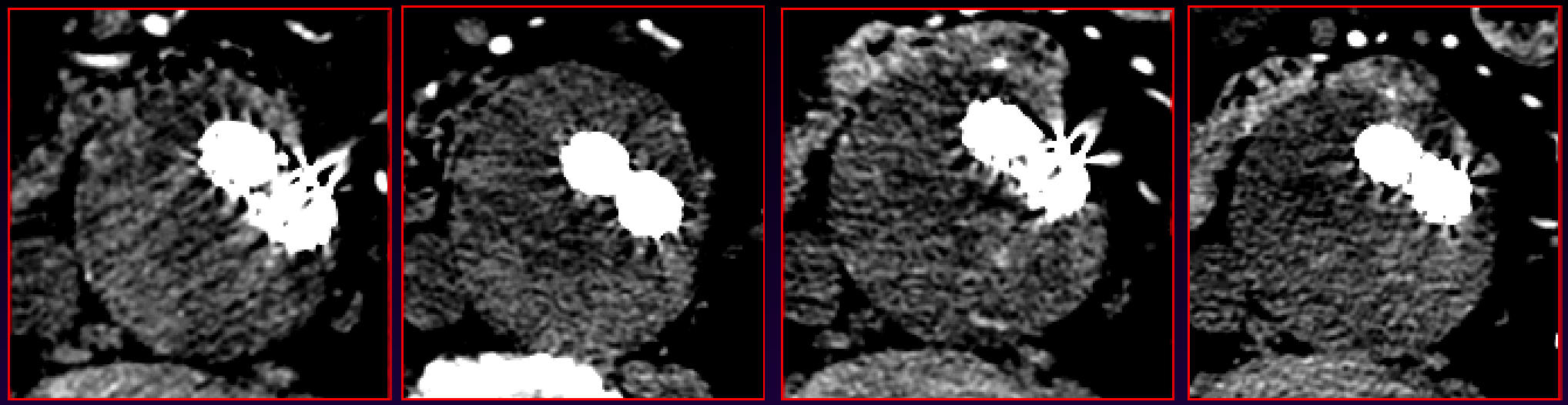

arterial phase (25 seconds)

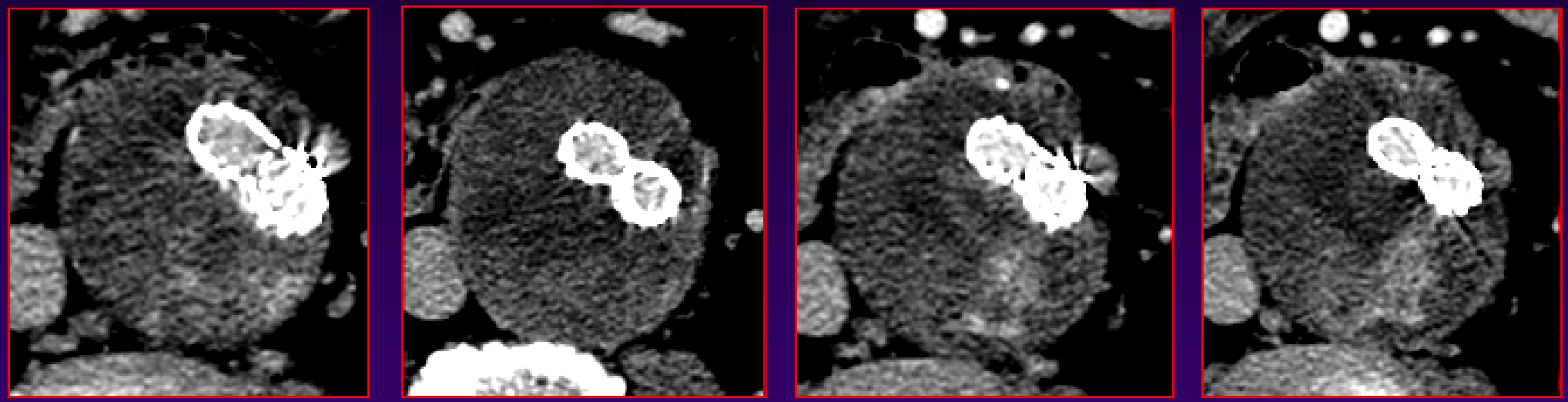

delay phase (75 seconds)

Large Endoleak

Delayed MR ~ 30 min.

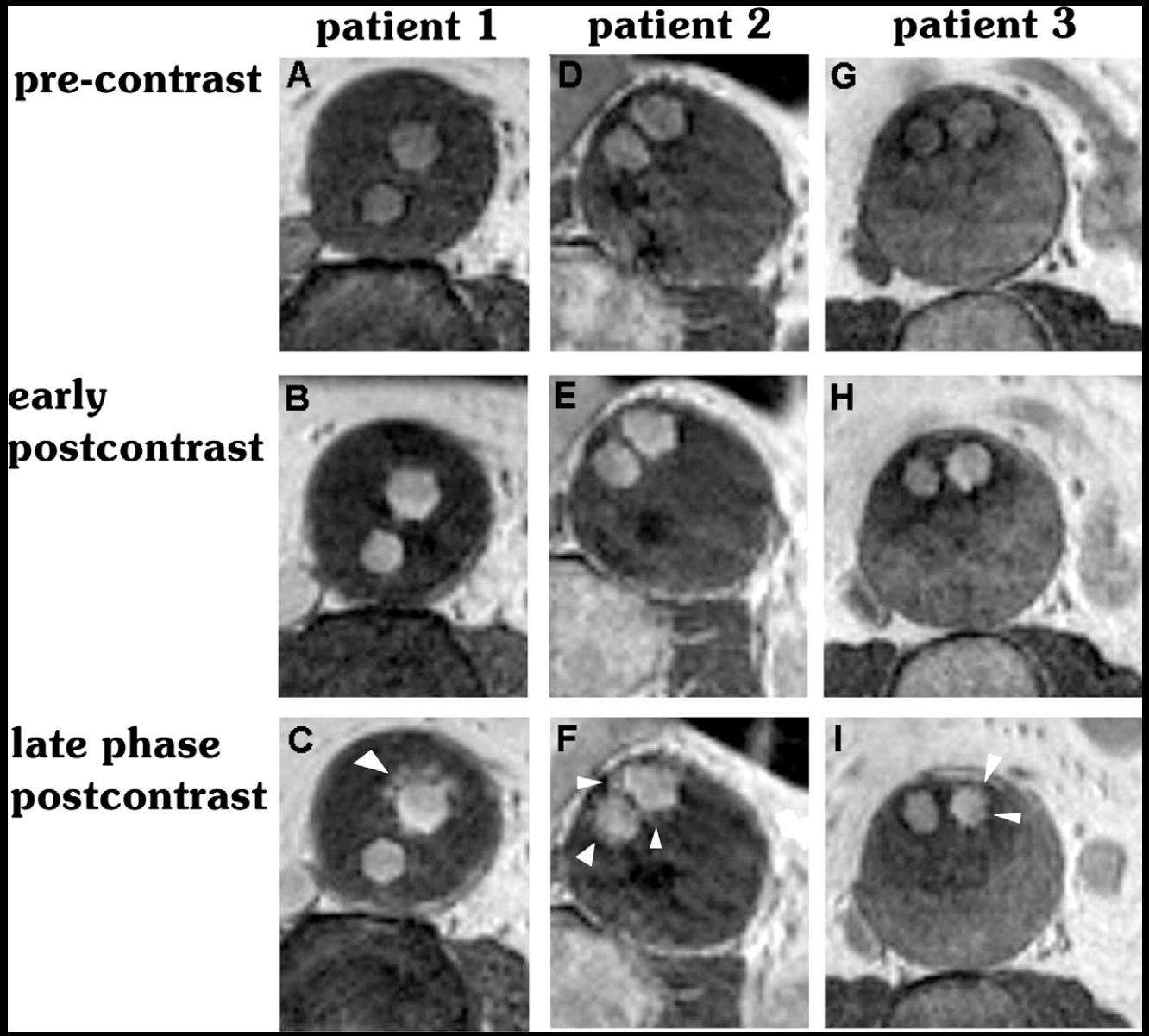

Cornelissen, et al. J Vasc Surg 2008; 47:861-4

Projectional Radiography

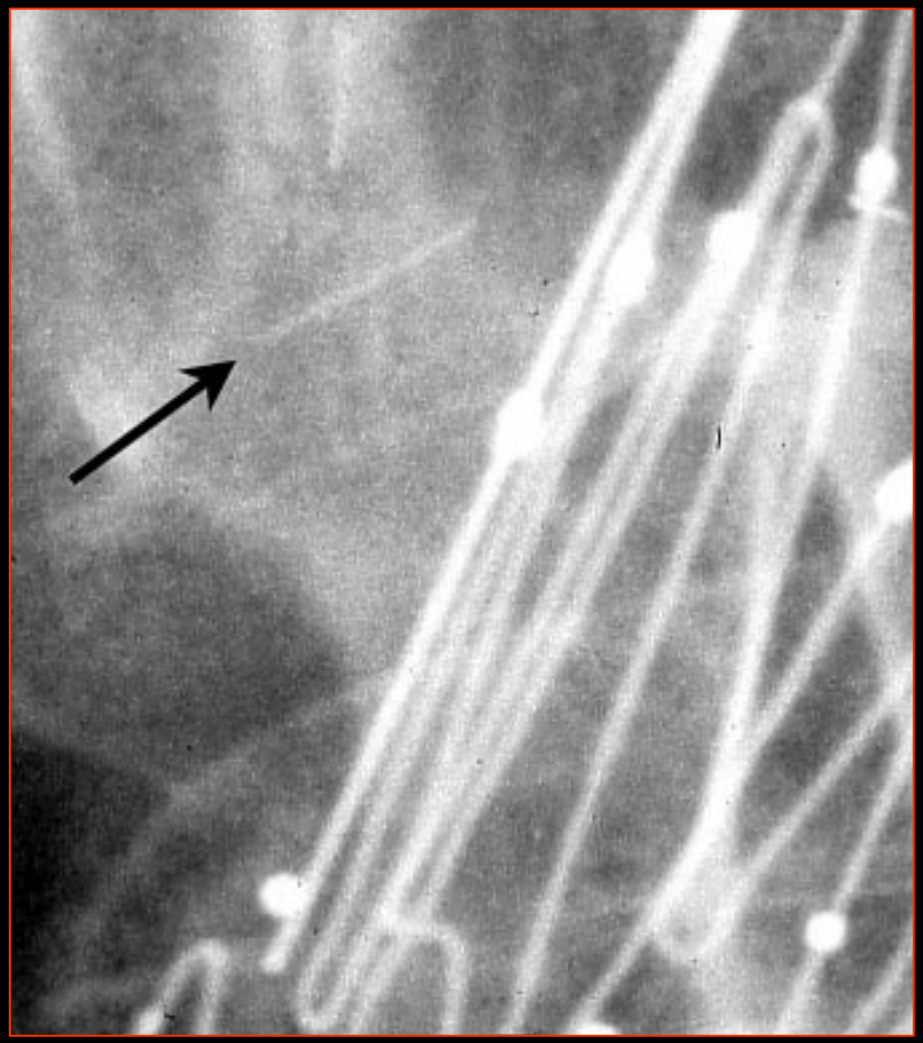

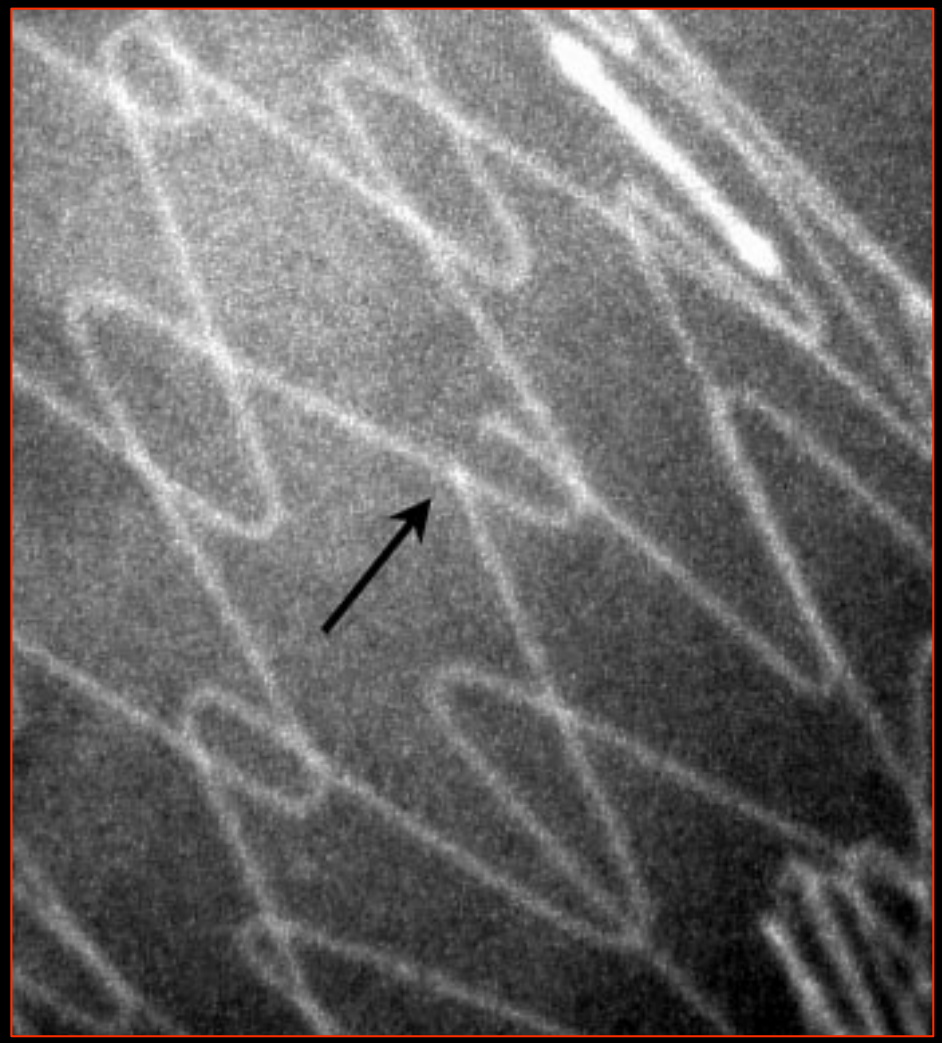

Radiography Challenges

- Overpenetration
- Underpenetration
- Scatter
- Motion
- Overlap with other device components
- Overlap with body tissues
- Landmarks

Ring & Suture Design

Diamond-shaped lattices



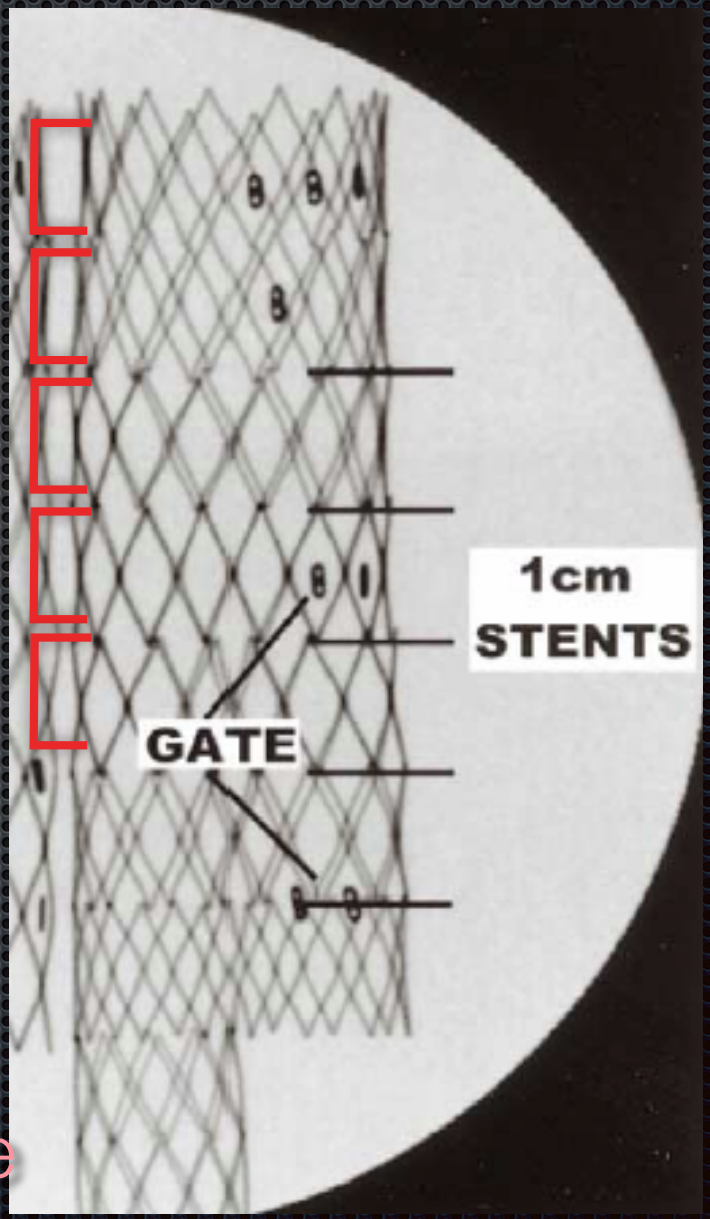

Sutures

Suture break



Metal fracture

Zarins et al. J Vasc Surg (2004) 40;1-11

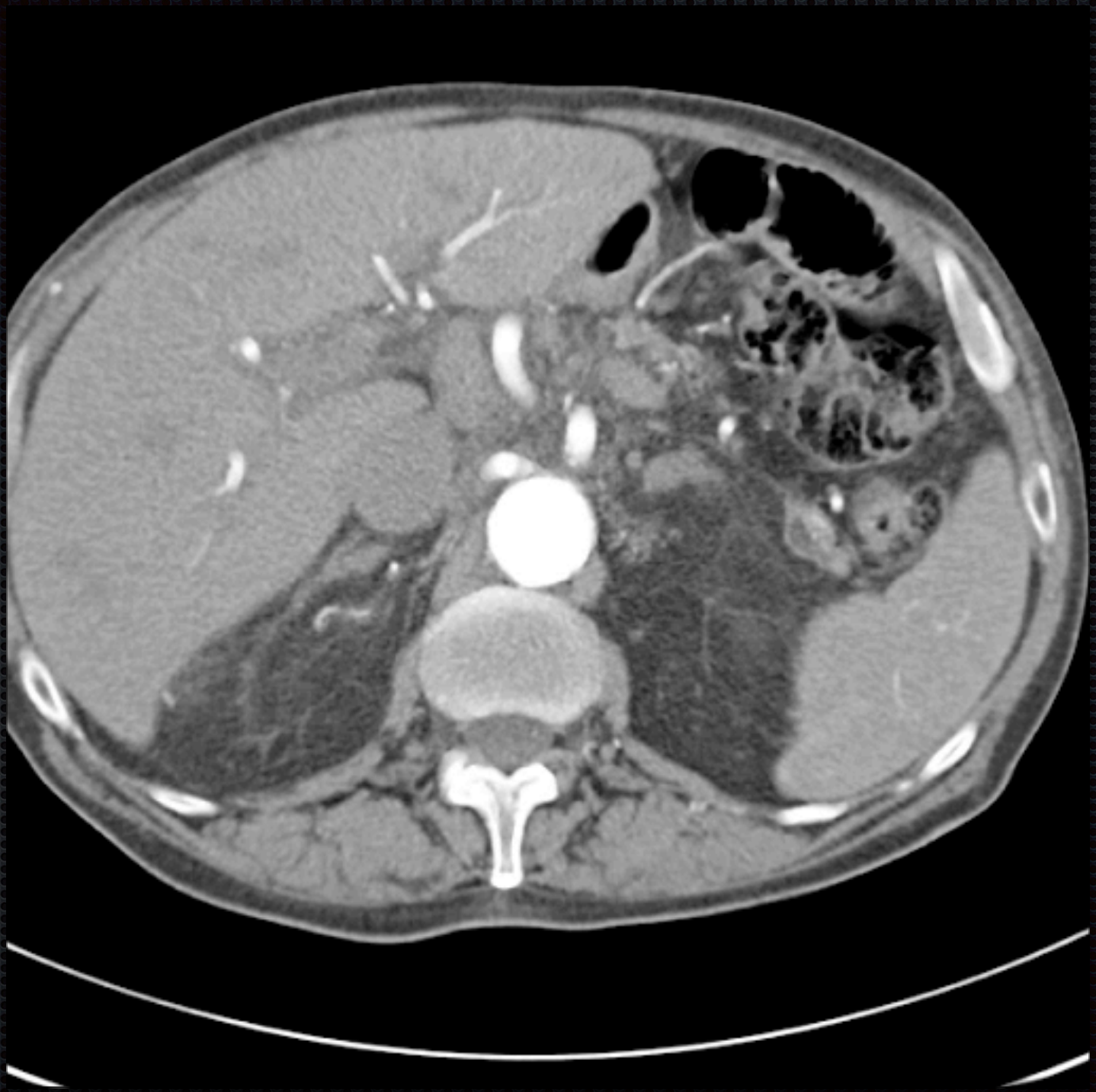

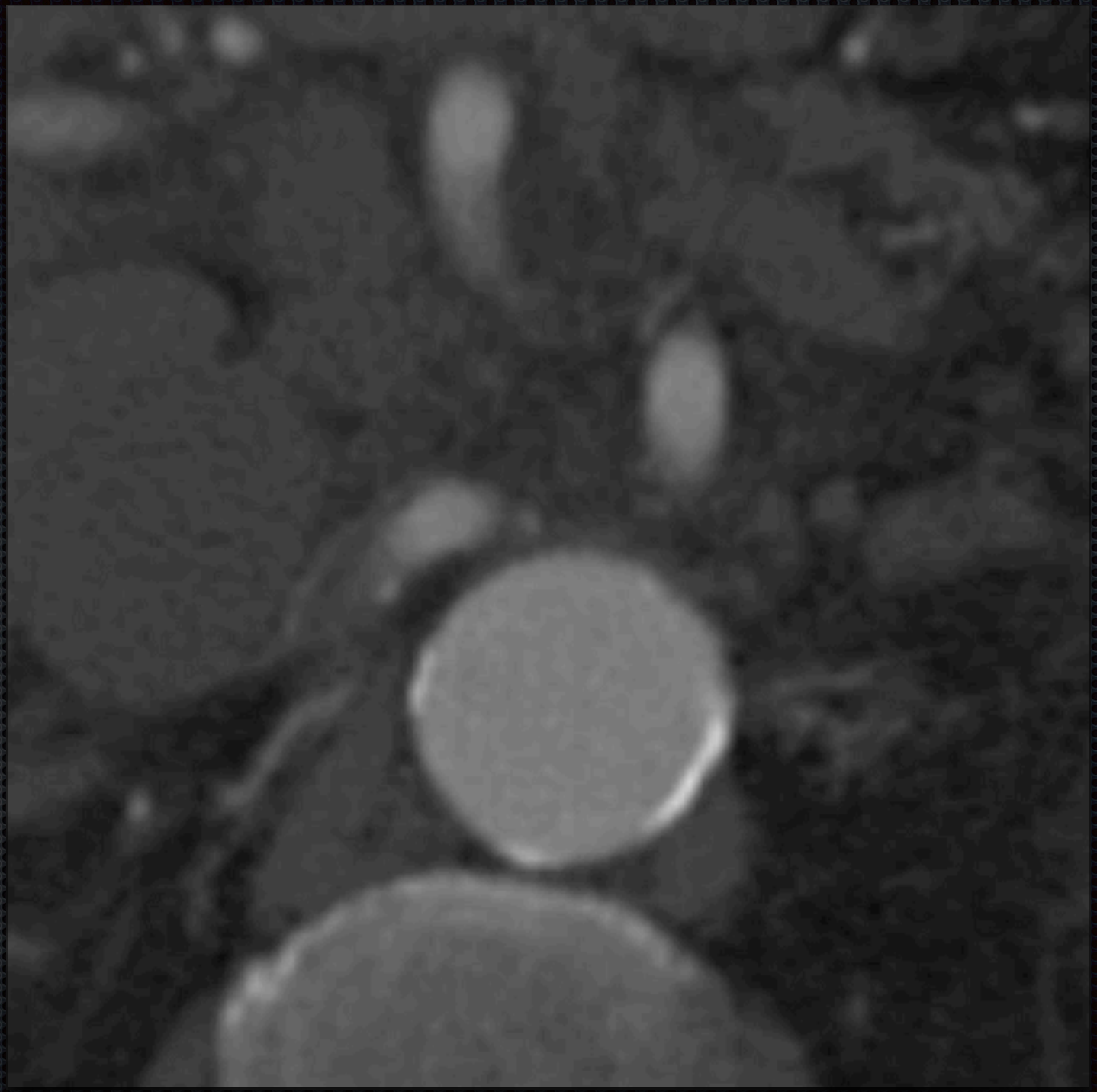

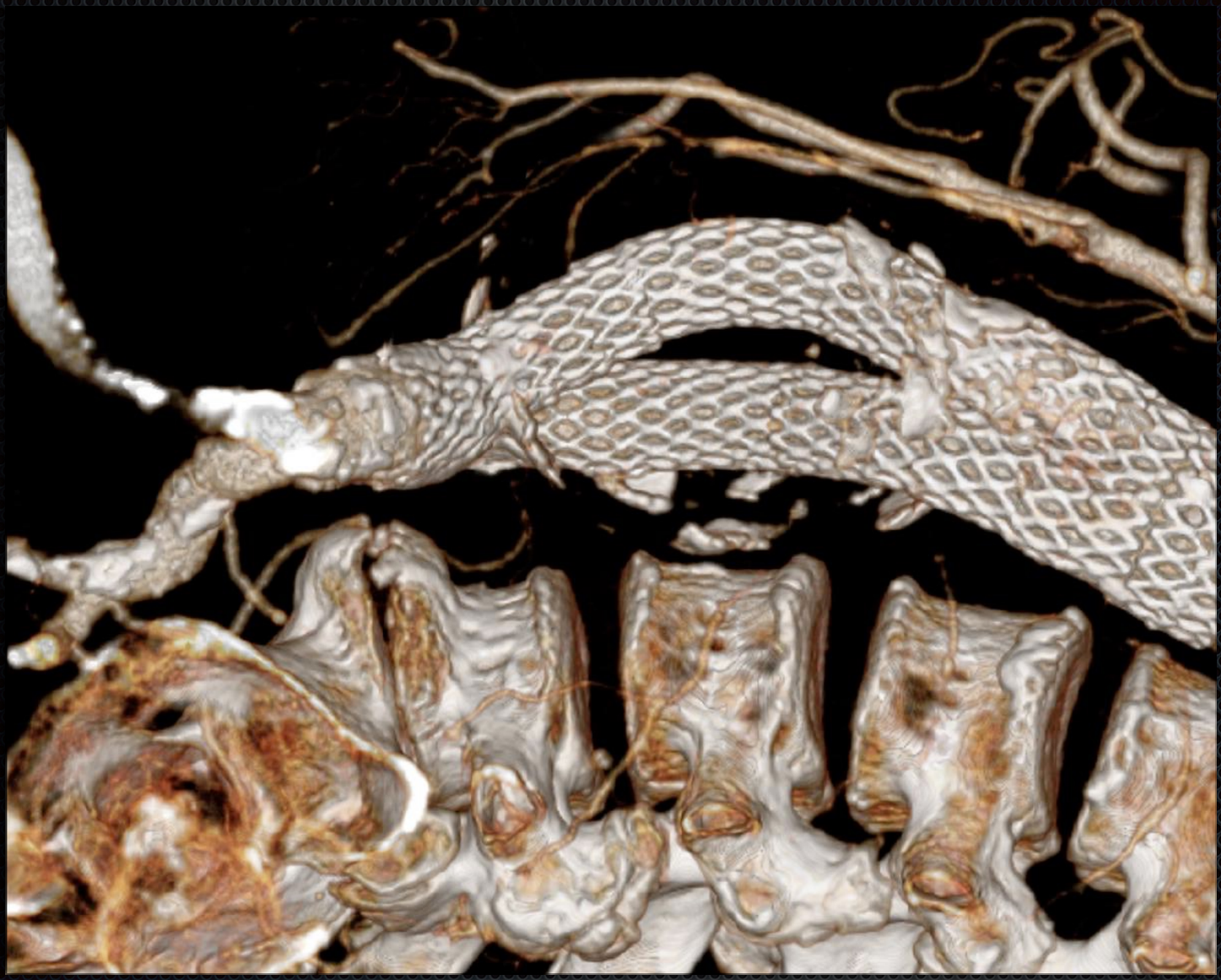





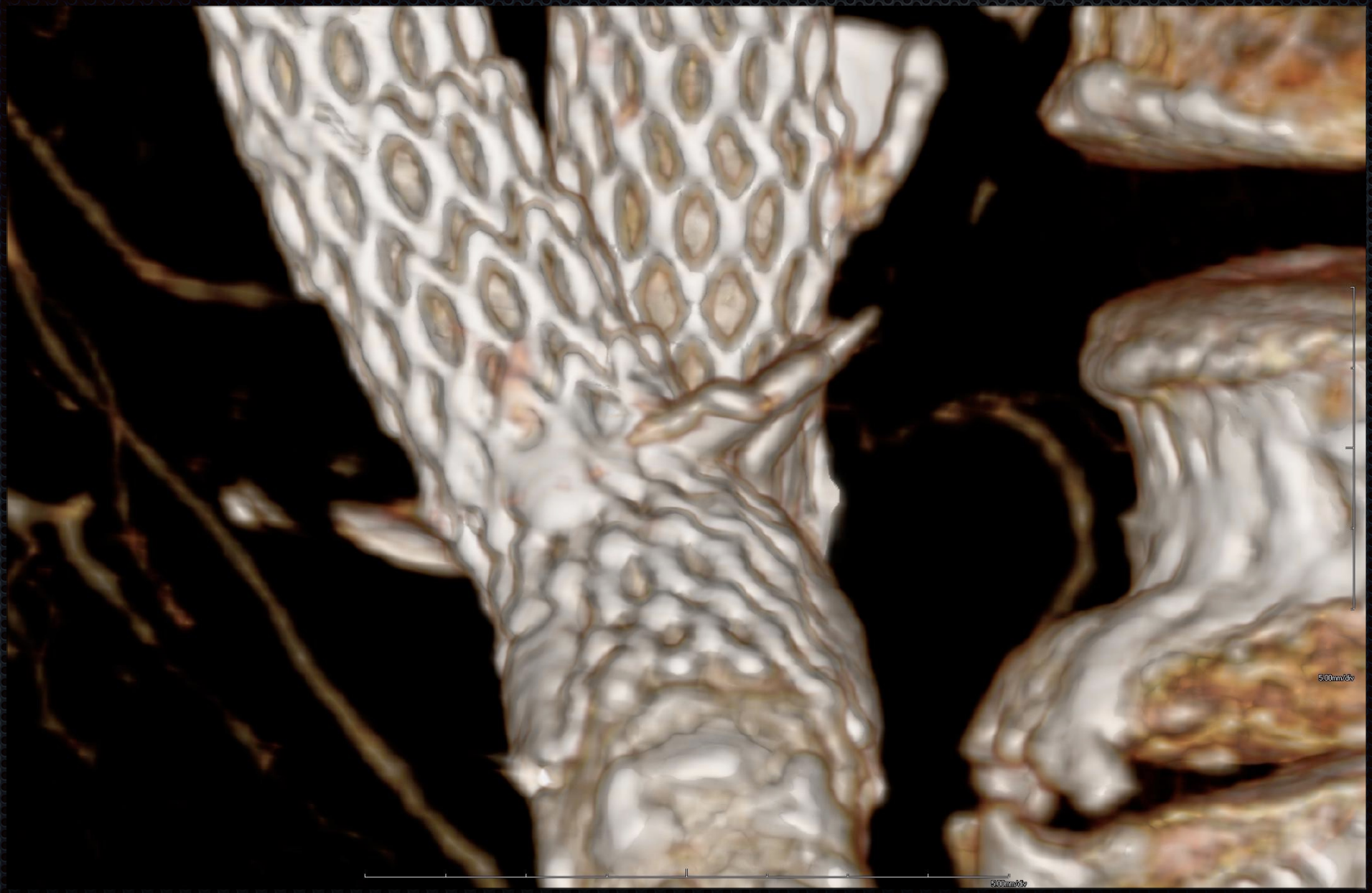
500mm/div
500mm/div

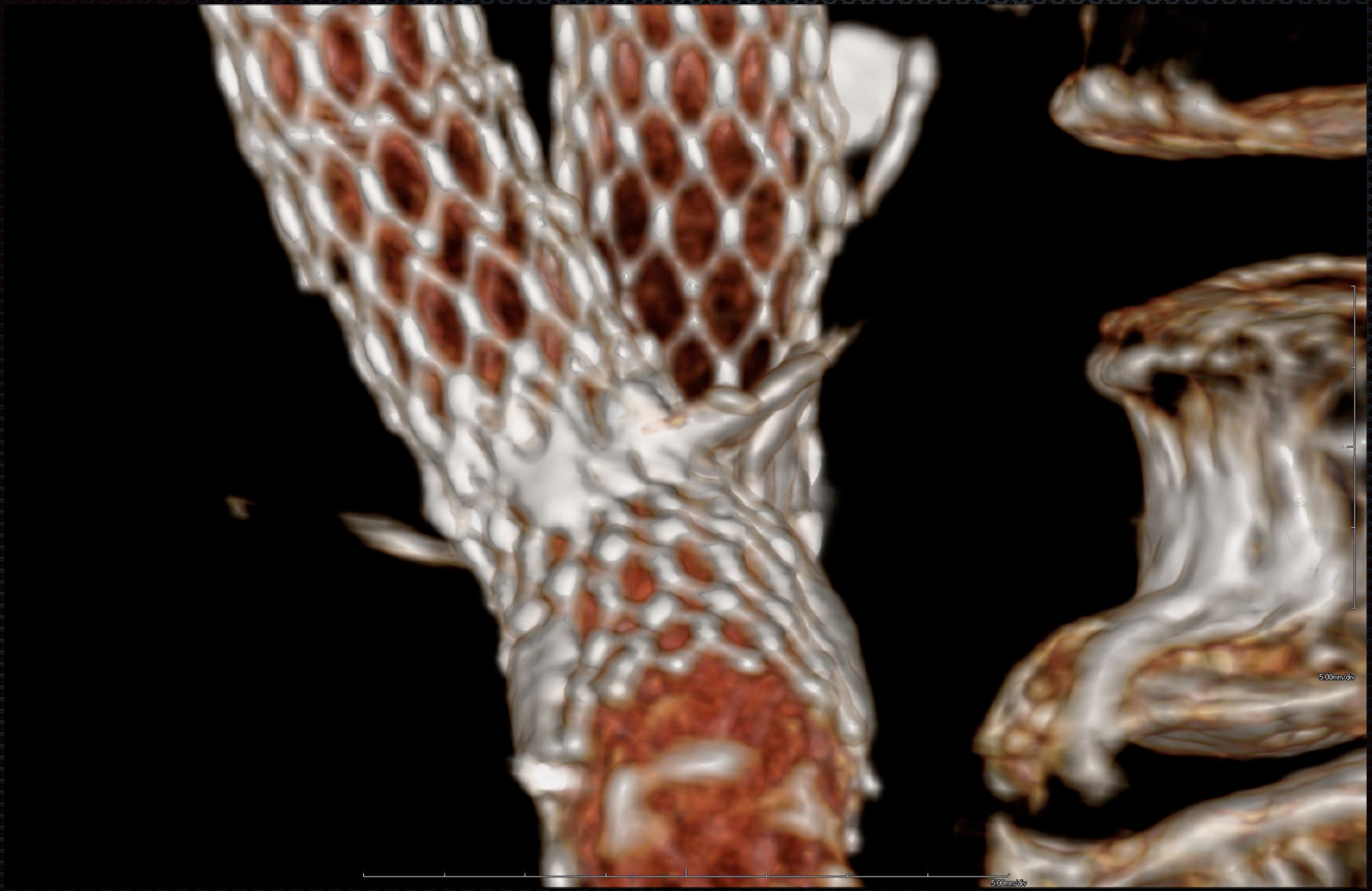
5.00mm/div
5.00mm/div

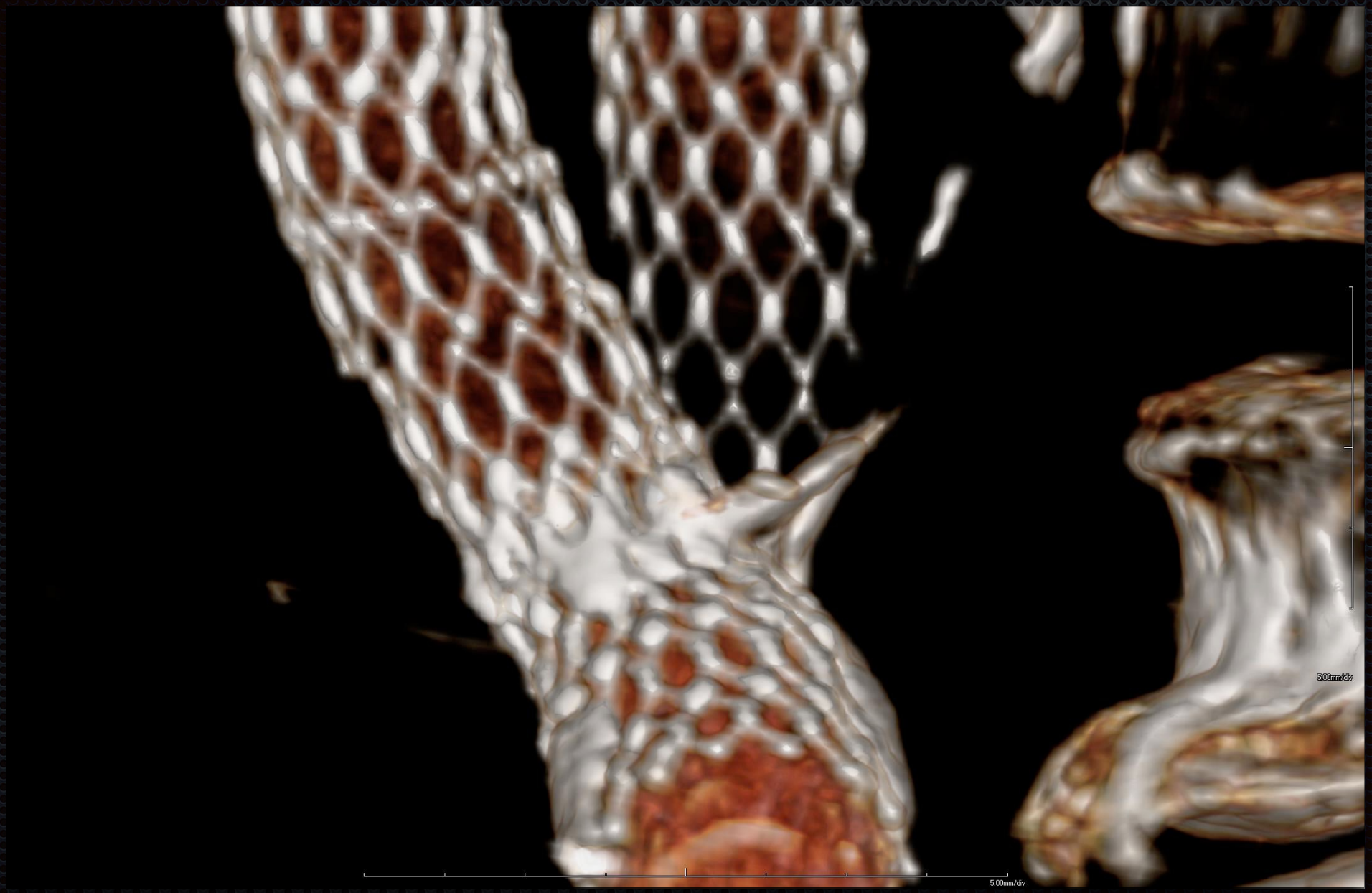
5.00mm/div
5.00mm/div

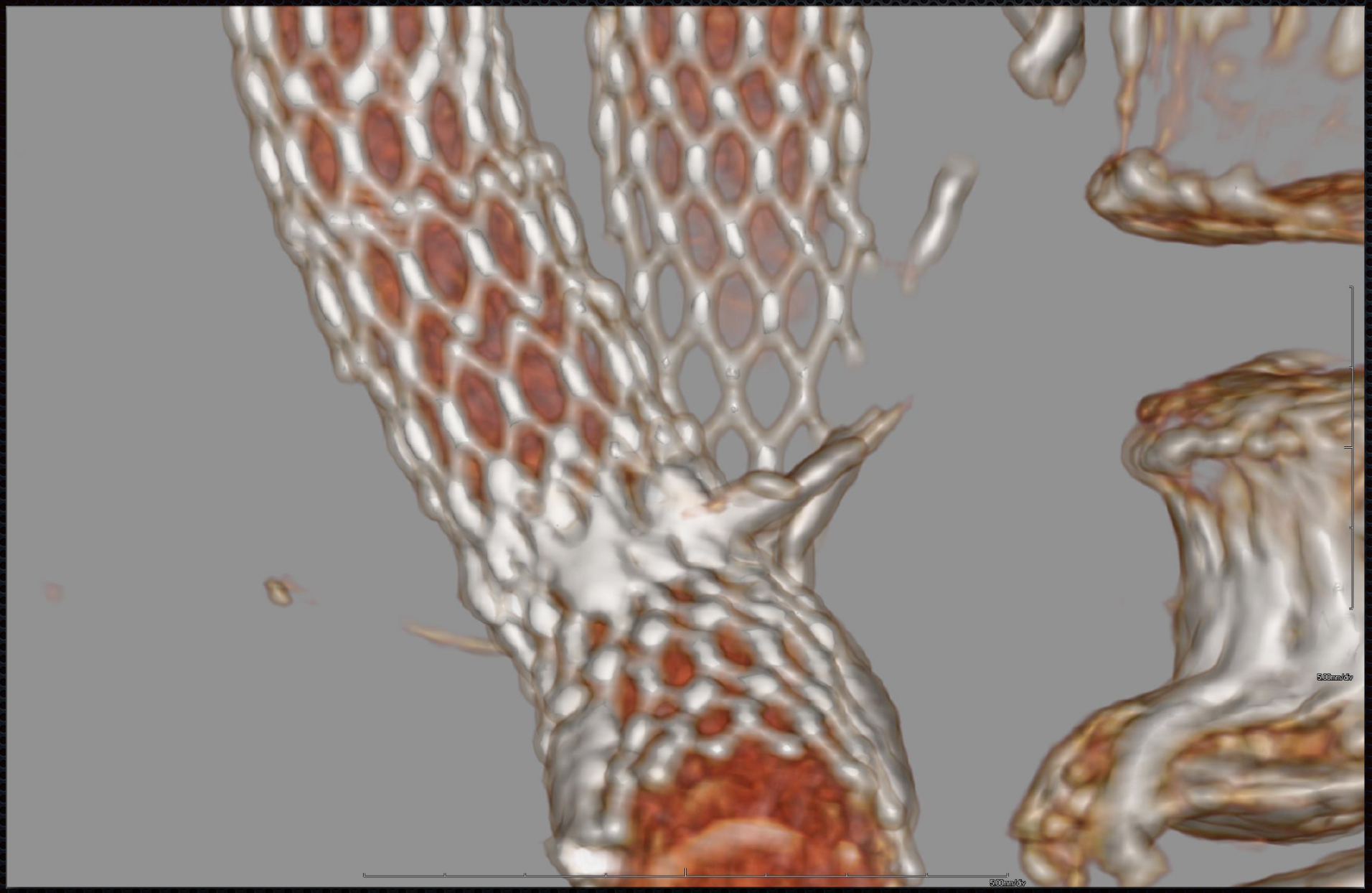
5.00mm/div
5.00mm/div

Secondary Intervention in 15/62 Patients

Complication	Re-Intervention	Severe Bk or Fx	
		Yes	no
Type I EL with migration	SG extension	5	0
Type III EL	SG extension (3) Open repair (1)	4	0
Migration w/o EL	SG extension	2	0
Type II EL	SG extension	0	3
Iliac occlusion	Fem-Fem Bypass	0	1

Ueda T, et al. Radiology. 2014 272:275

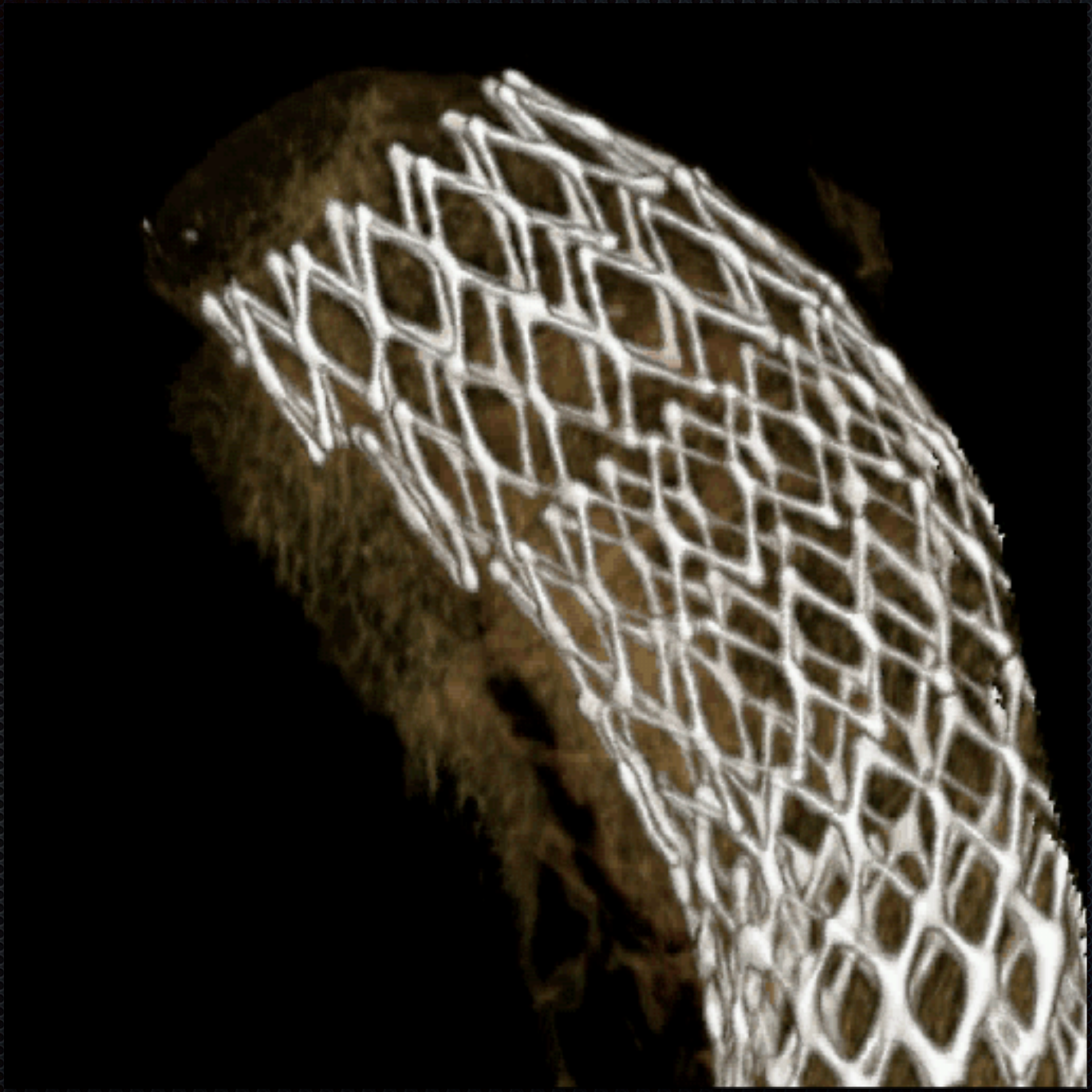

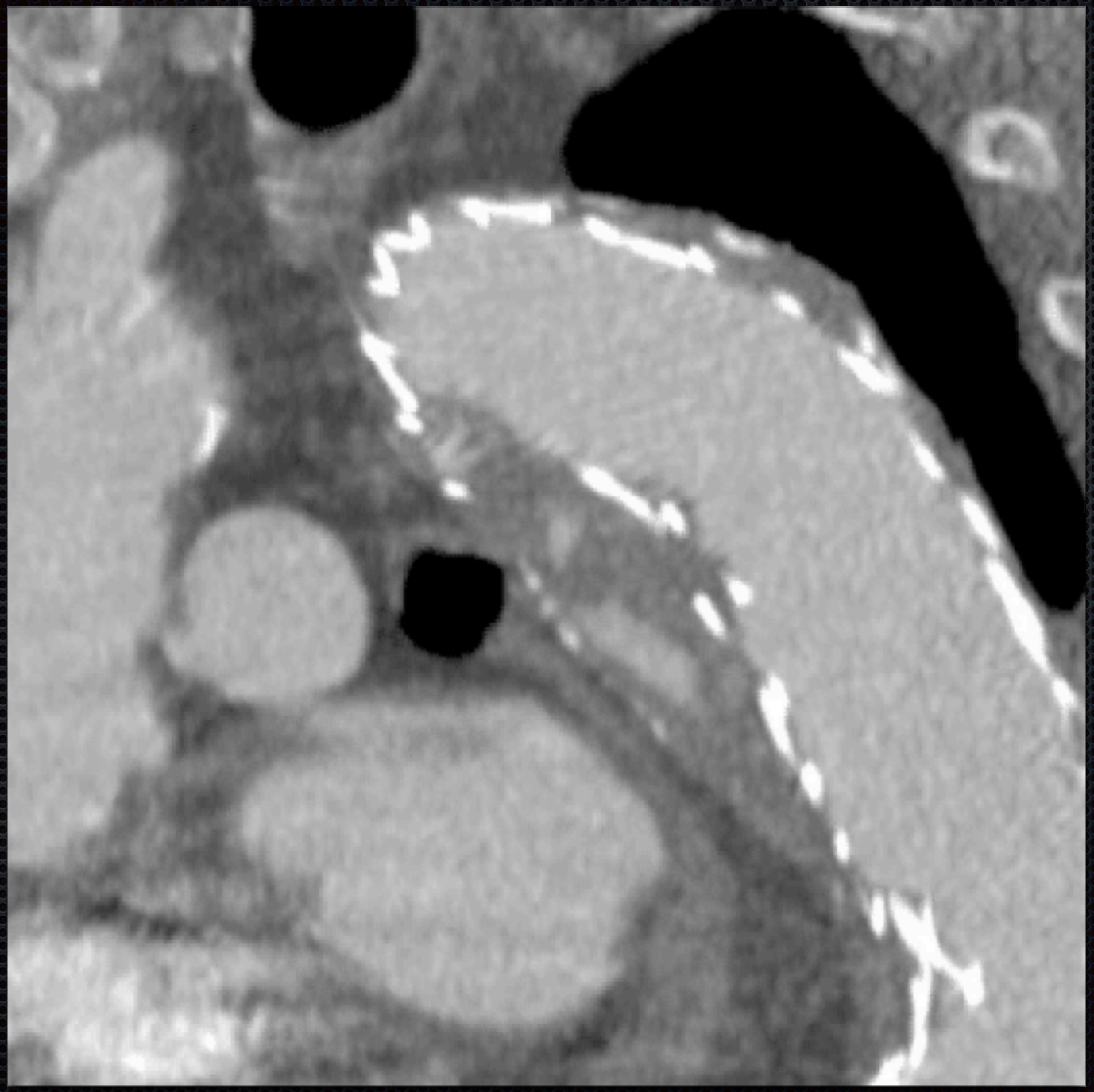

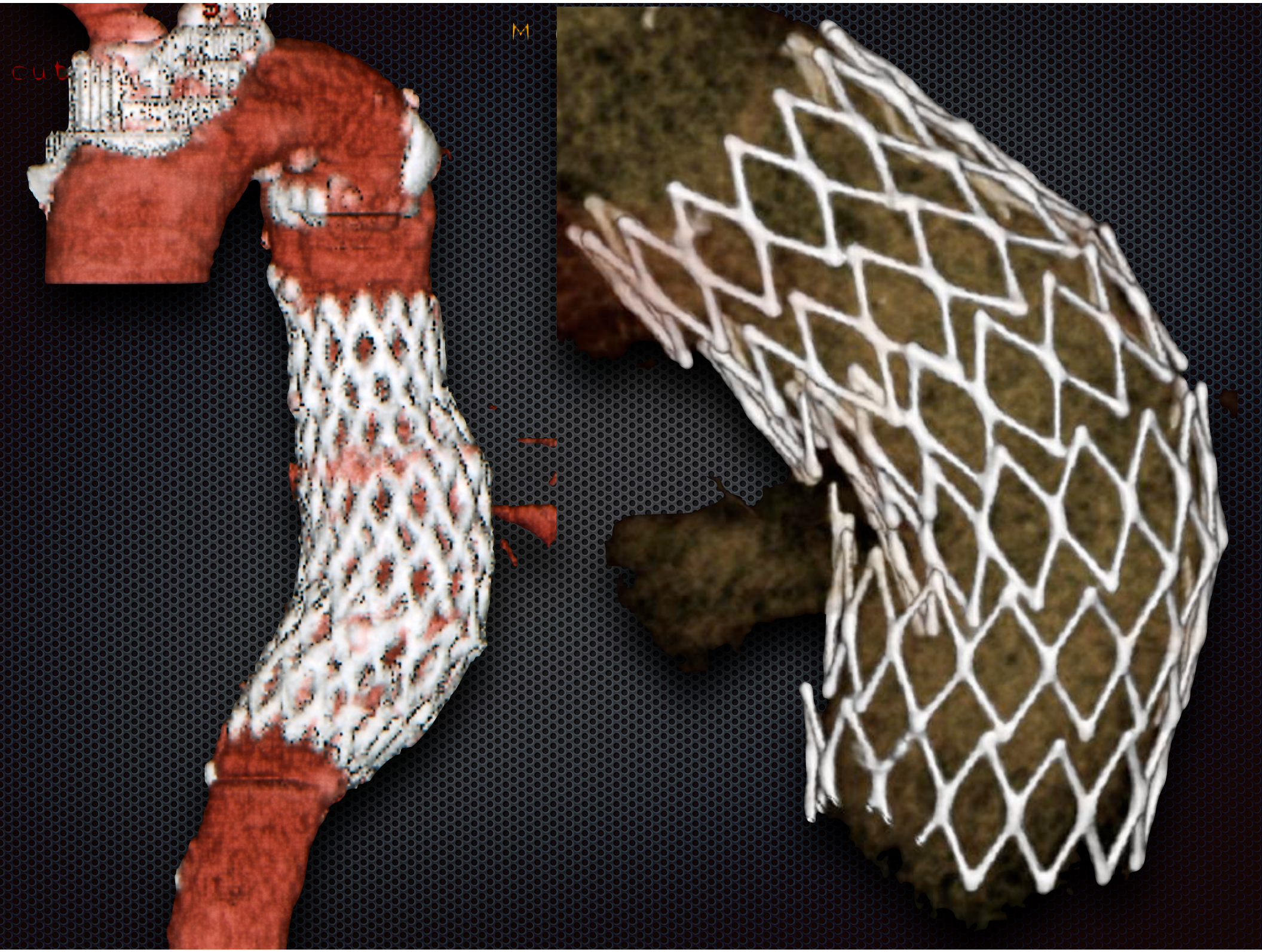
cut
M

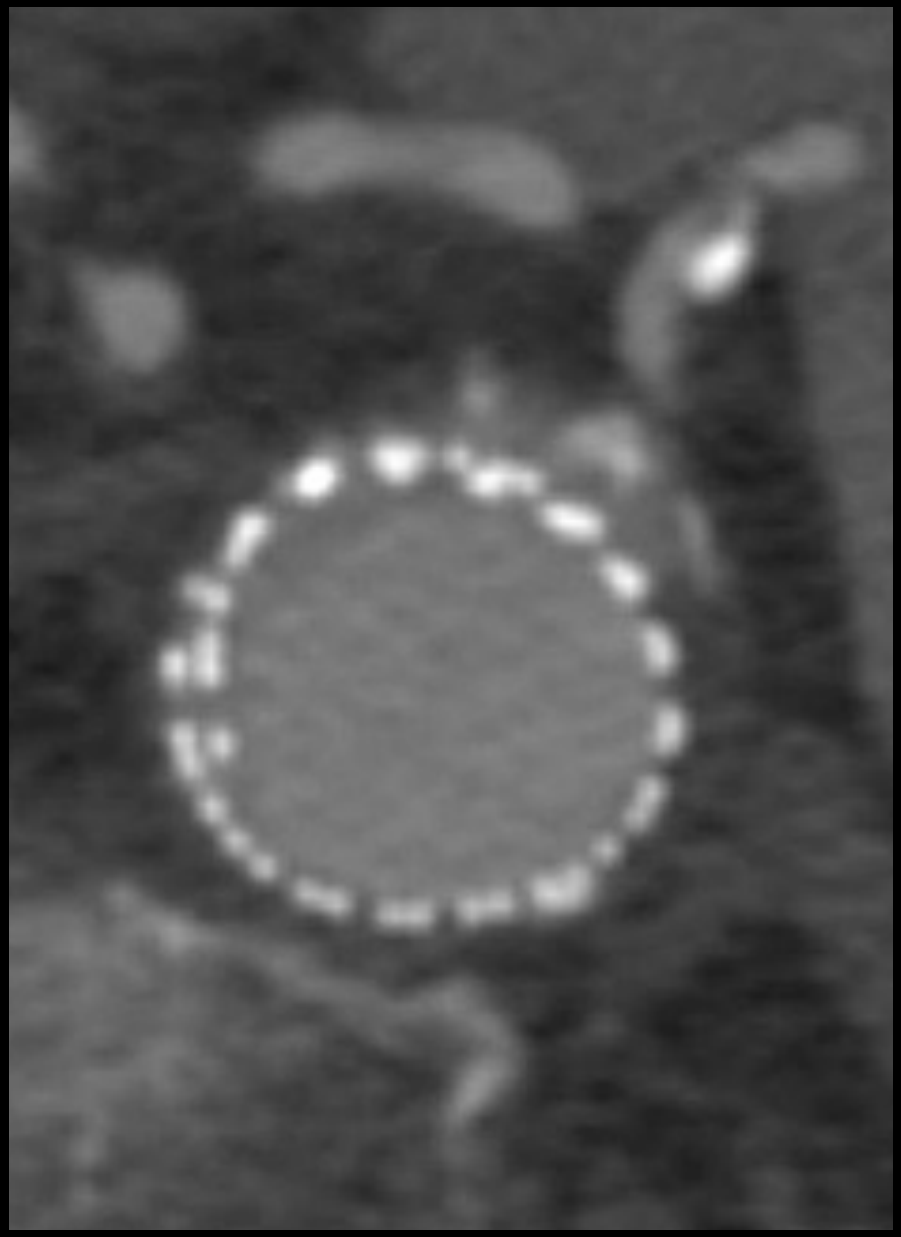

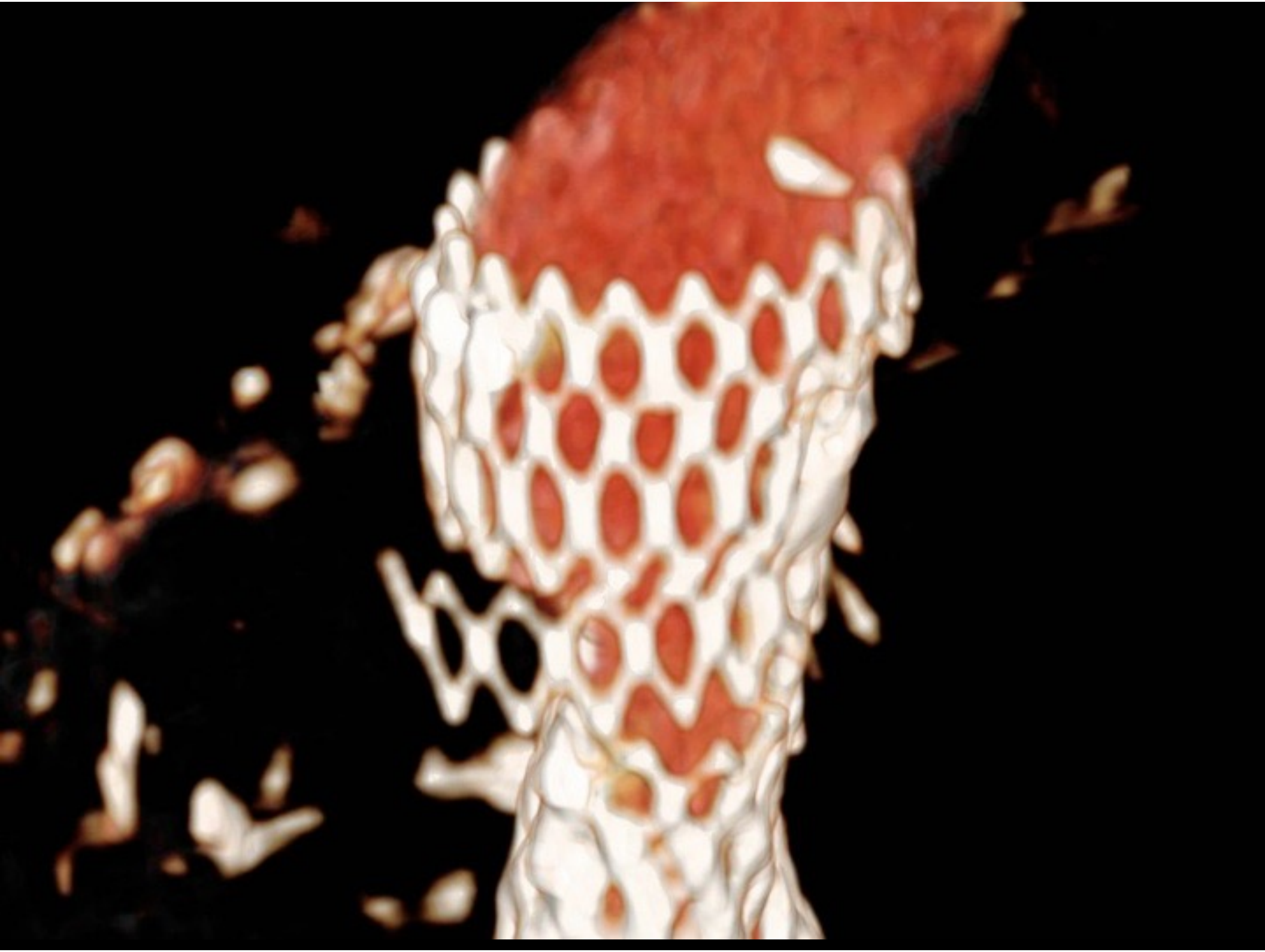

25 month interval

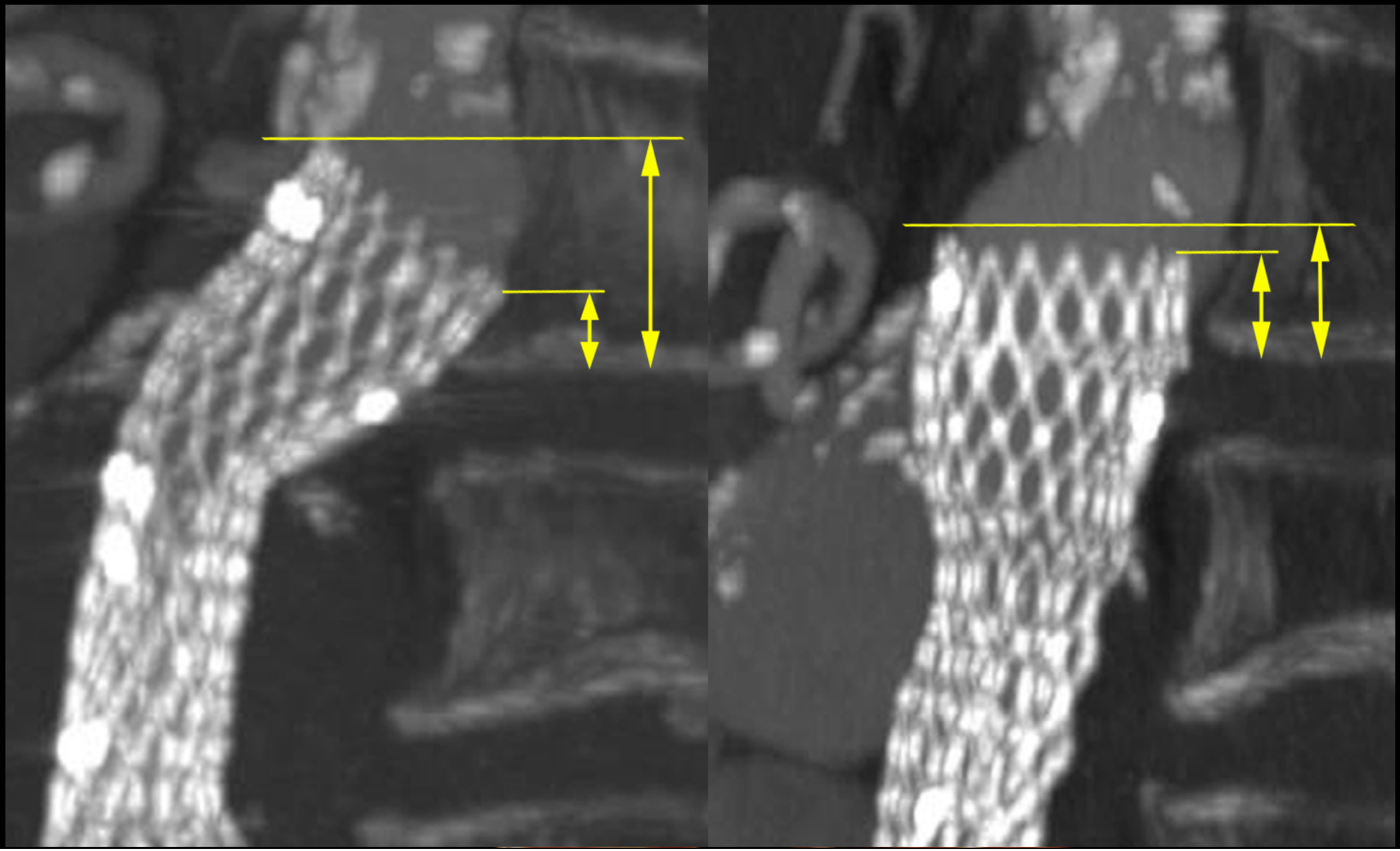

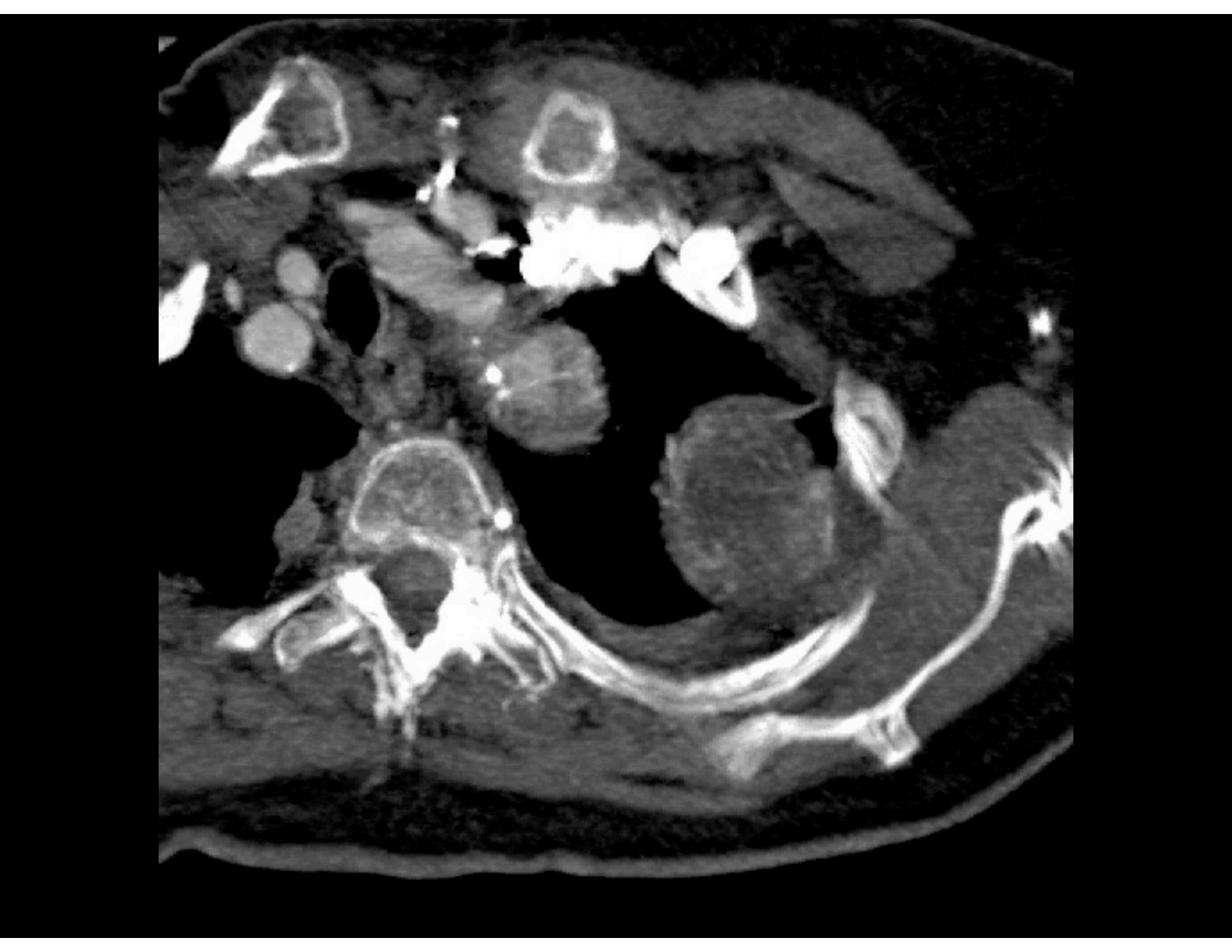

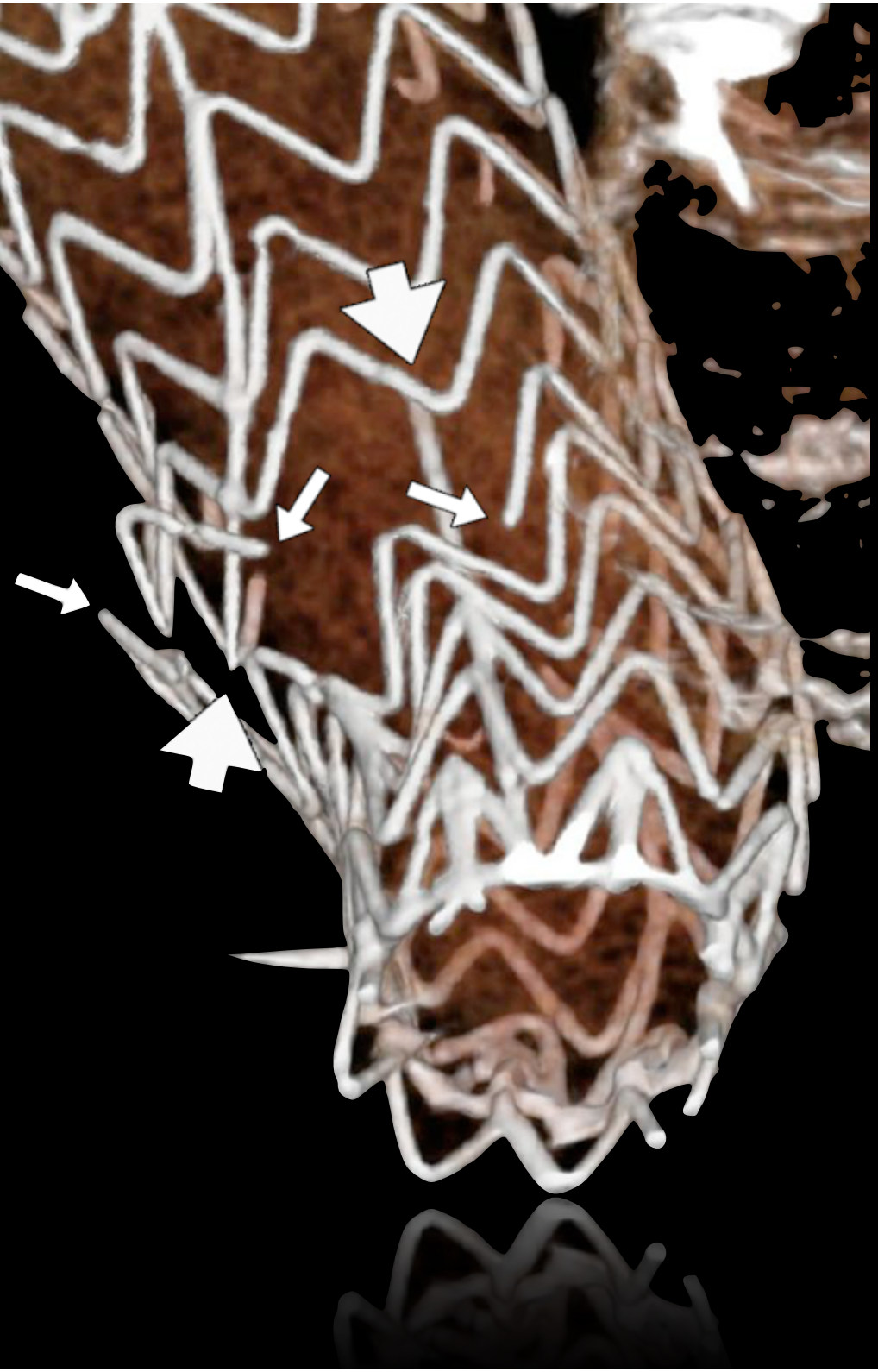


A
T
T

11 Months post-Deployment

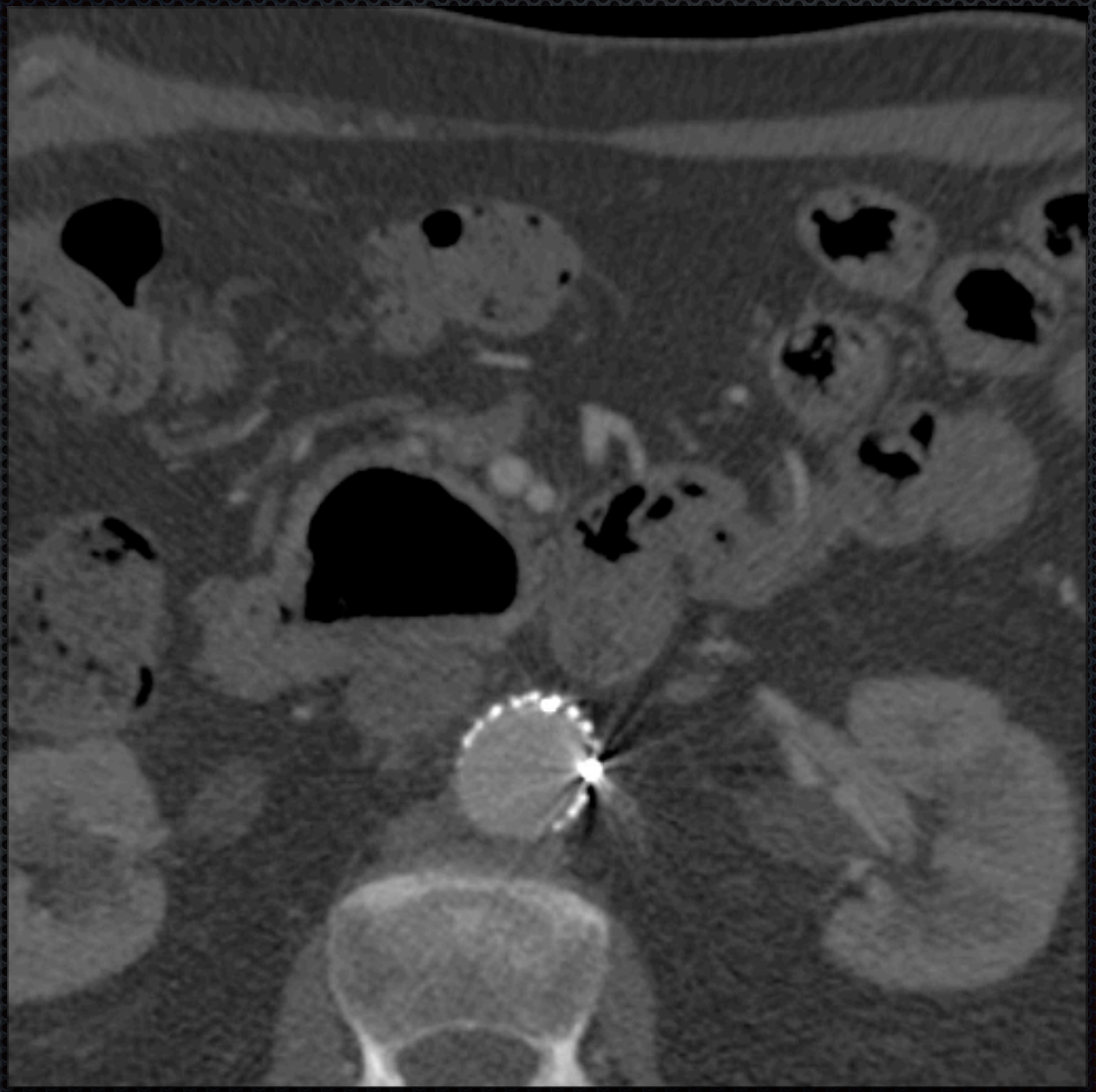

Acute Abdomen 6 Months Later

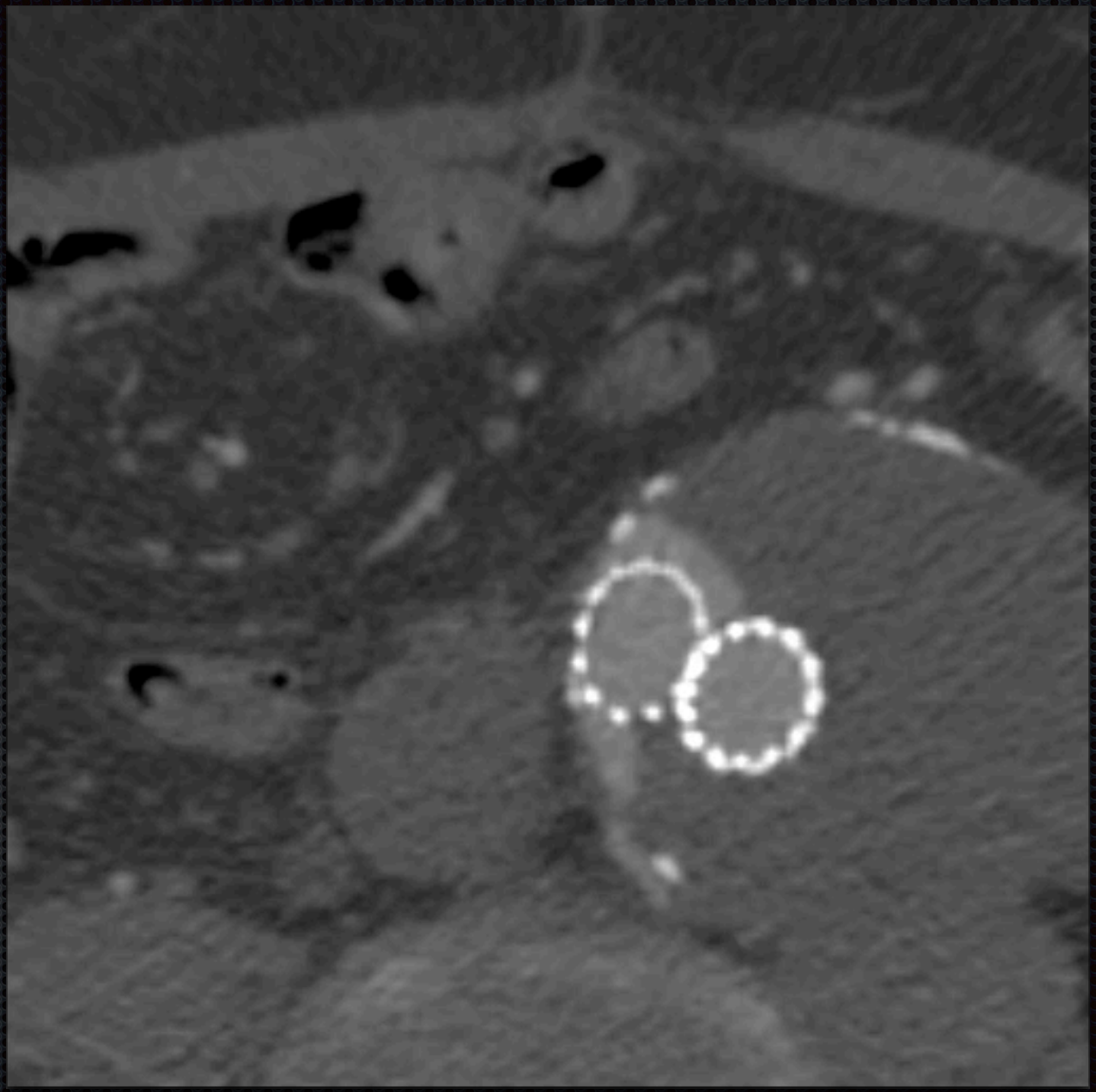

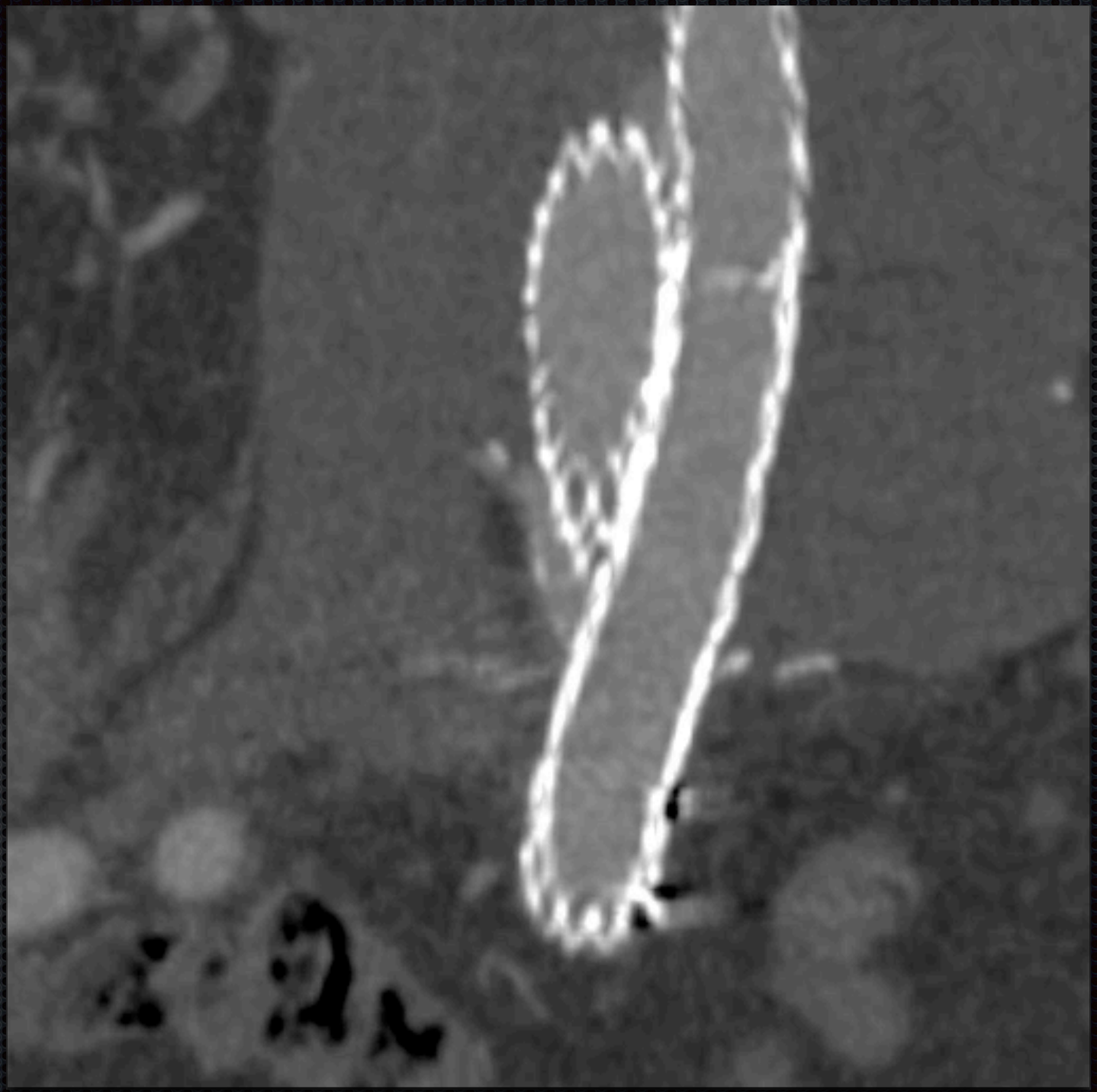

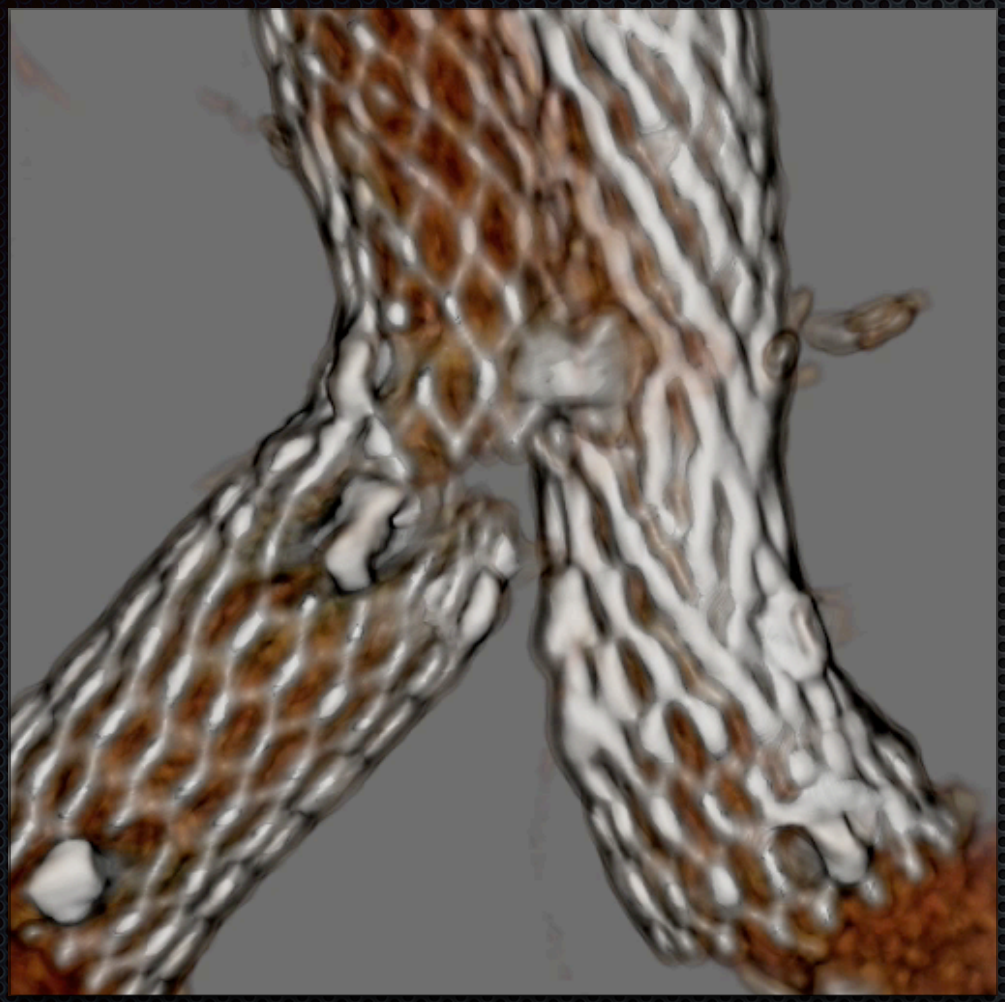

Volume Rendering

Near-complete limb fracture 11 mos. post deployment

Likely fabric tear and Type III endoleak

Acute Abdomen 6 Months Later

Acute Abdomen 6 Months Later

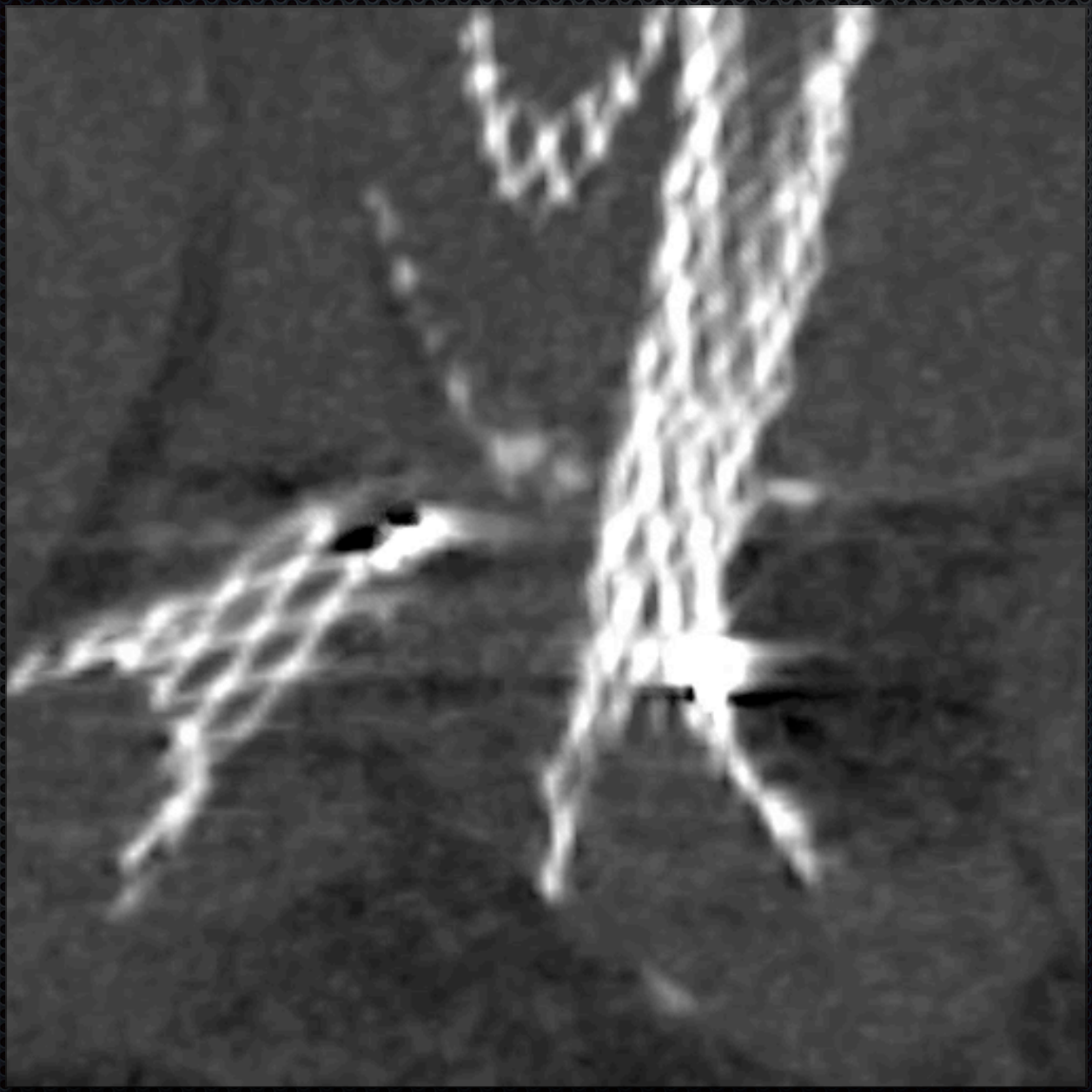



Unenhanced CT: Aneurysm Rupture & Type III Endoleak

- Sac dimensions & character
- Stent-graft integrity & position
- Retroperitoneal hematoma




Length: 6.28mm


Length: 15.96mm


Length: 1.52mm


Length: 12.81mm

Main Message

The detection of important complications relating to stent-graft depolyment requires high-resolution triphasic acquisitions to detect the diverse abnormalities of the aneurysm sac, the aortic branches, parenchymal organs and the metallic endografts.