The Image Processing Workstation: An indispensable tool for CT interpretation

Geoffrey D. Rubin, MD.

Data Explosion in Imaging

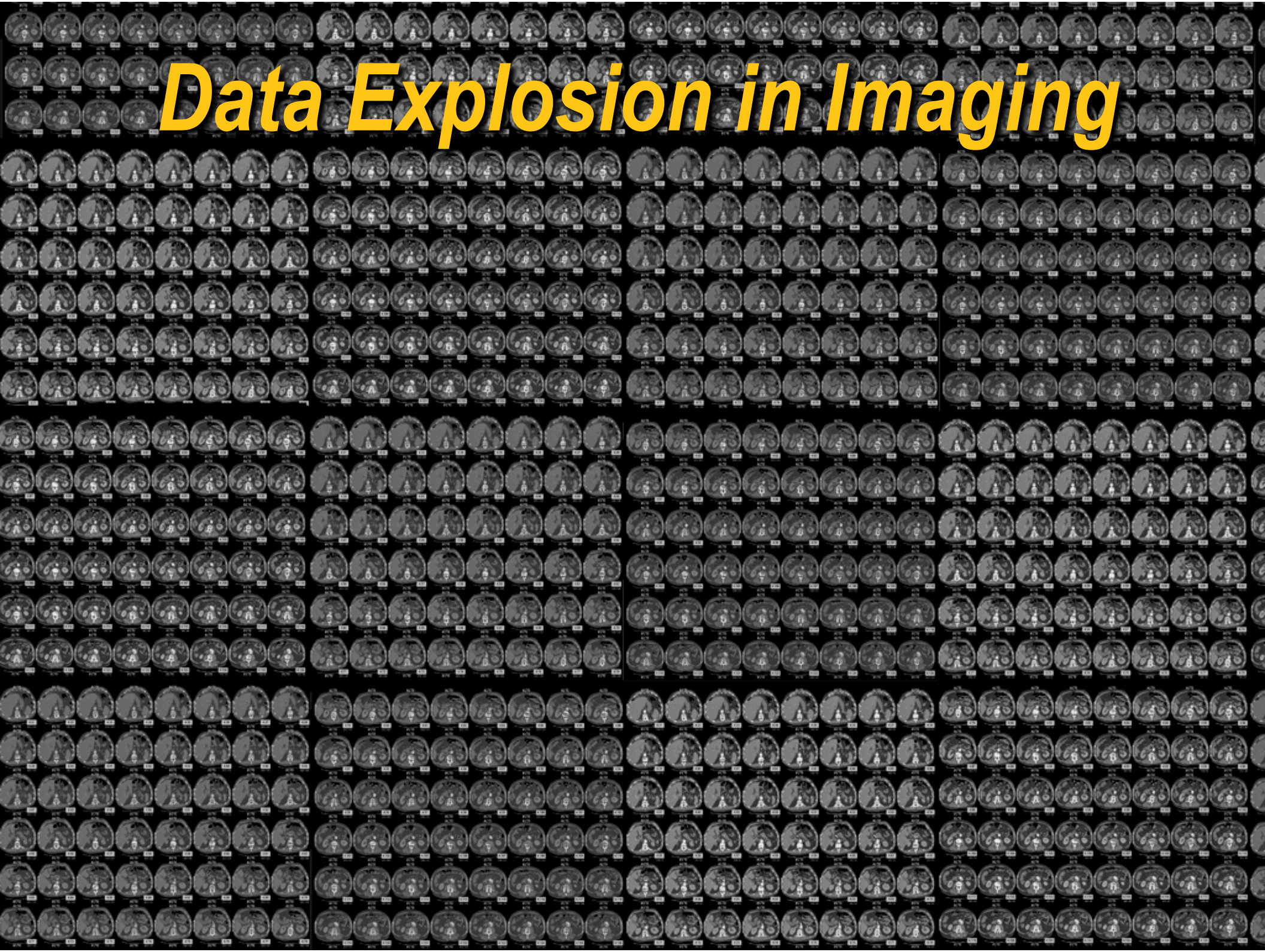

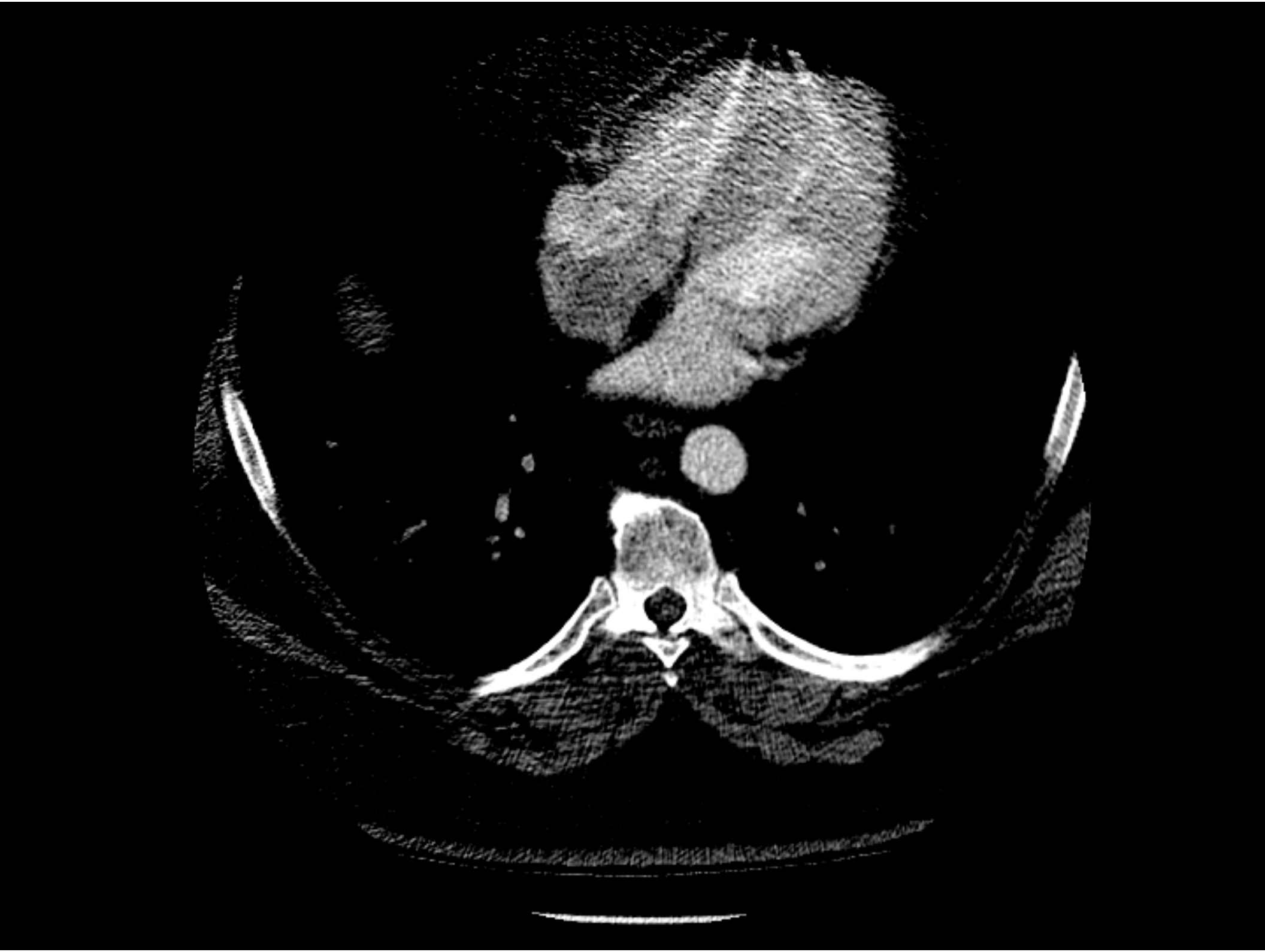

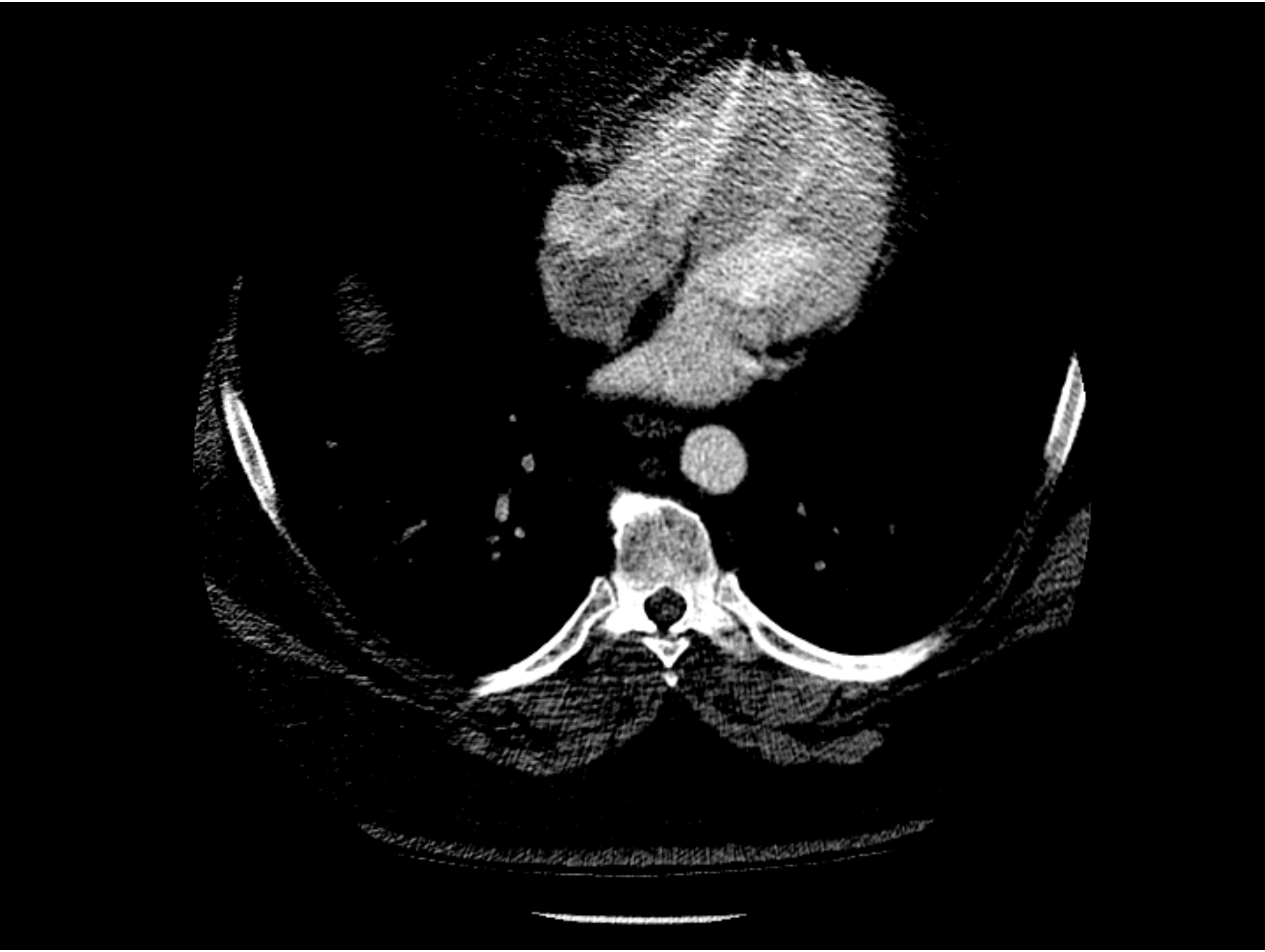

Rationale for 3D and 4D Analysis

- Anatomically (not CT table) directed visualization and quantitation
- Time-varying information
- Efficiency
- Intuitive image presentation for referring physicians

Tibial Plateau Fracture

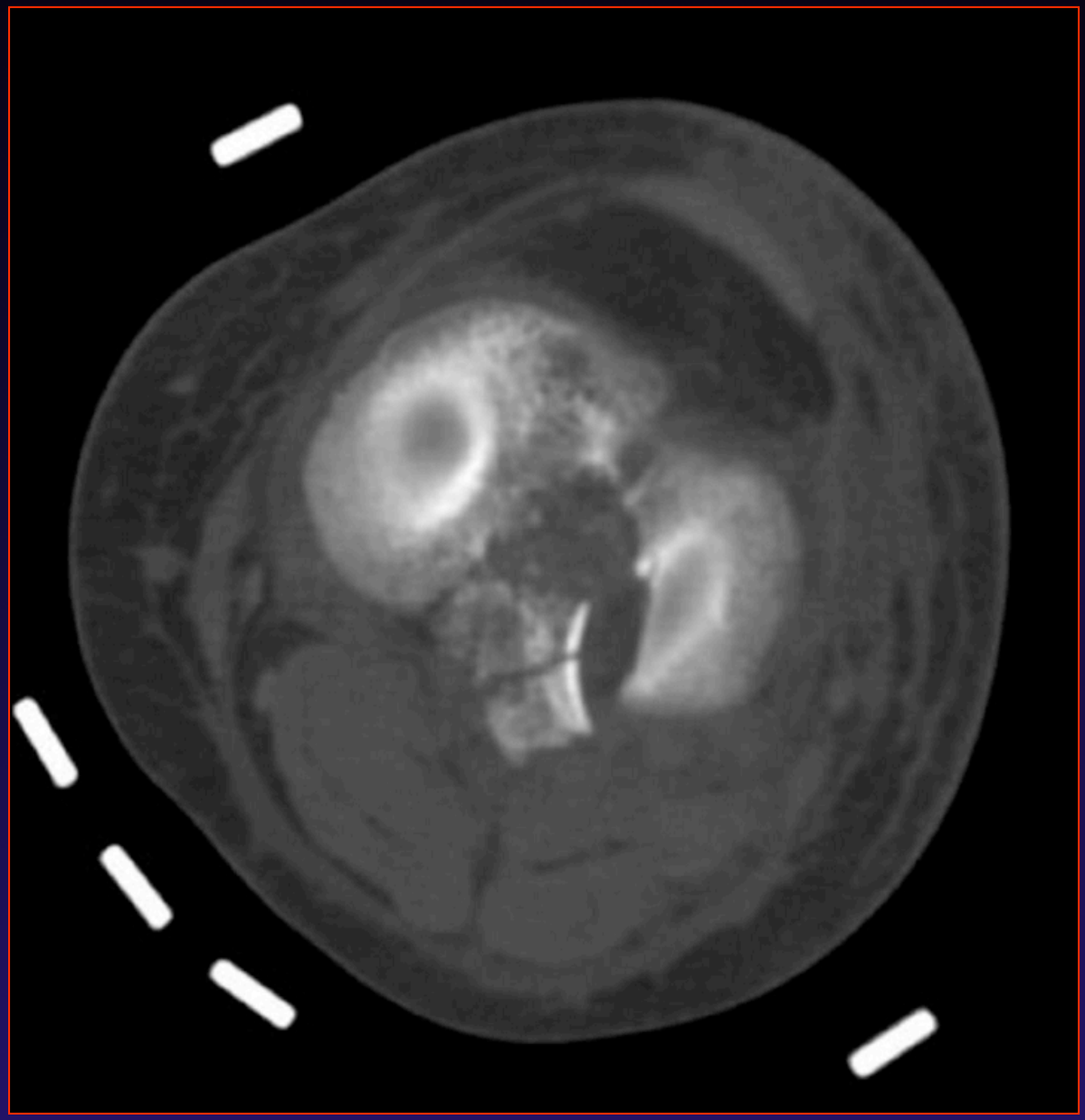

Multiplanar Reformations (MPR)

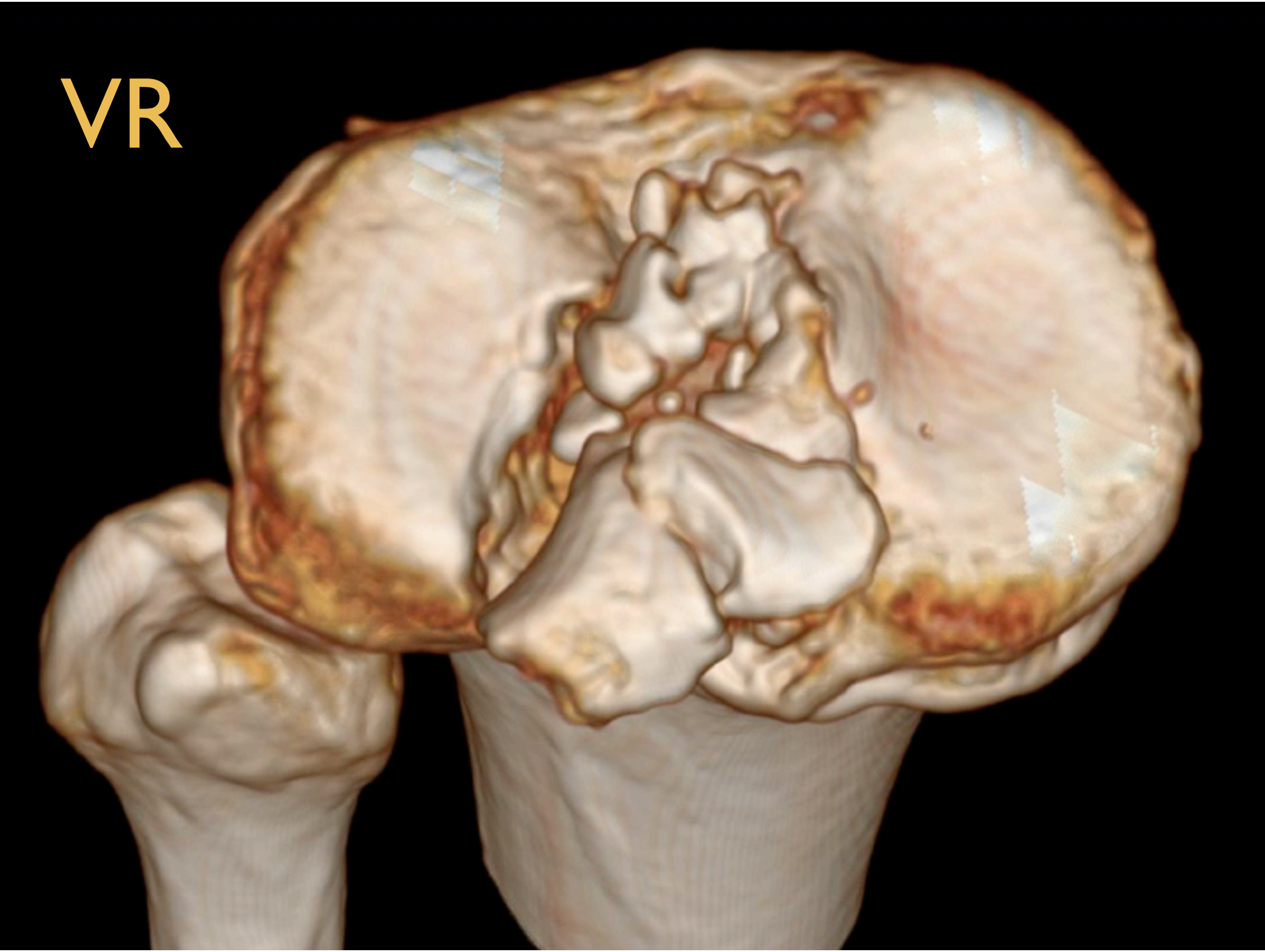
VR

Infundibular Stenosis



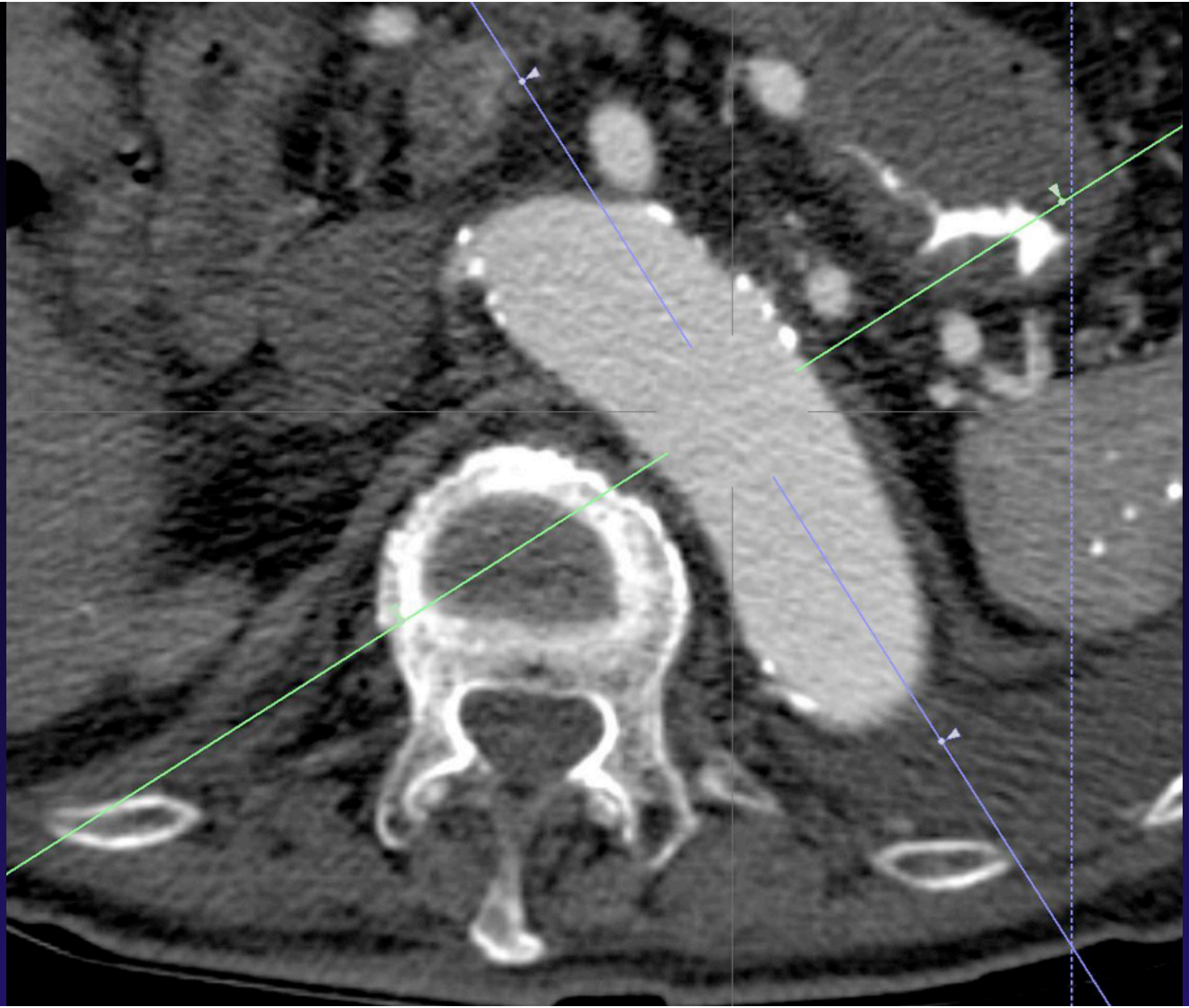

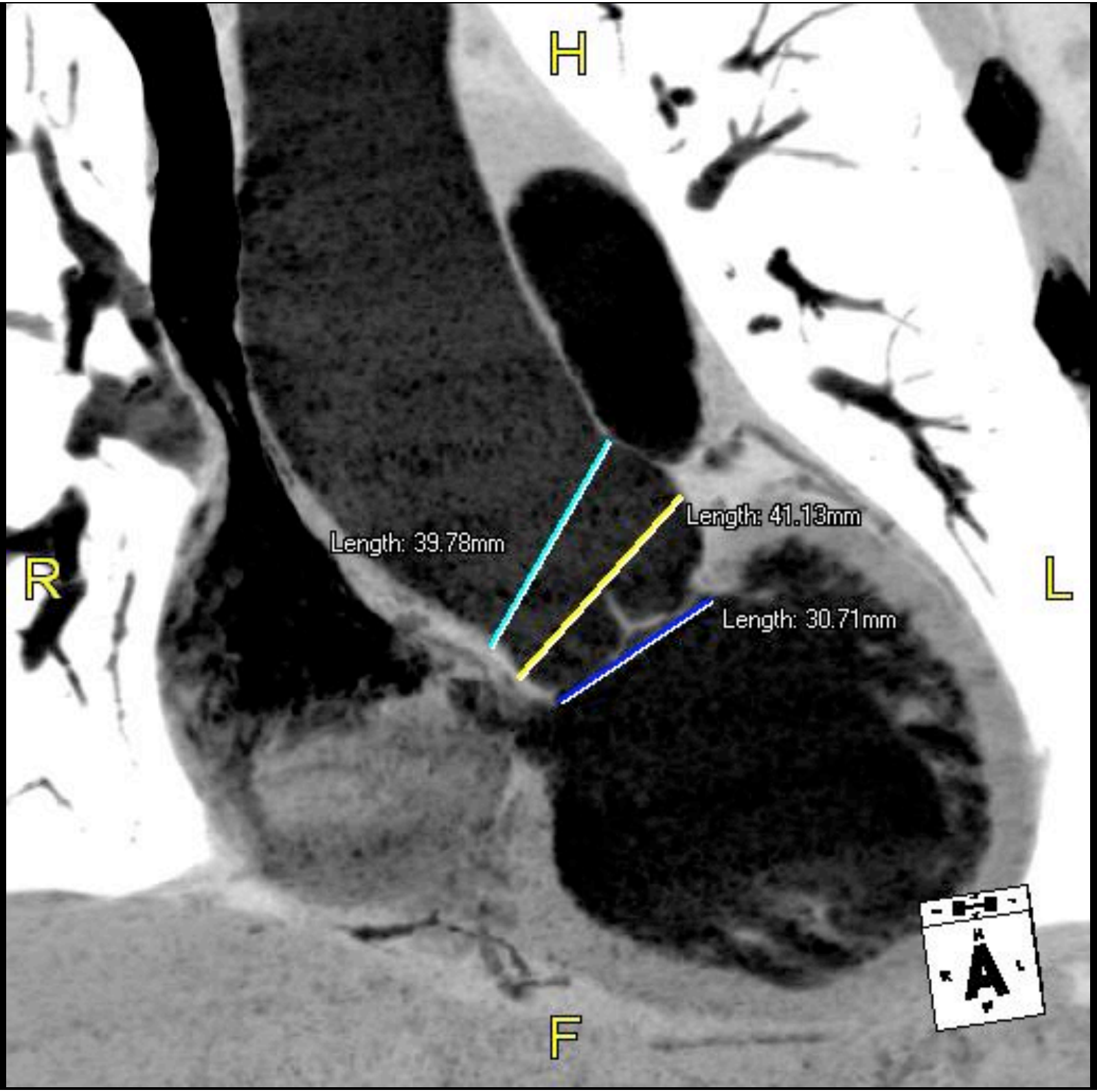
H
R
L
F
A
Length: 39.78mm
Length: 41.13mm
Length: 30.71mm

Arterial Stenosis

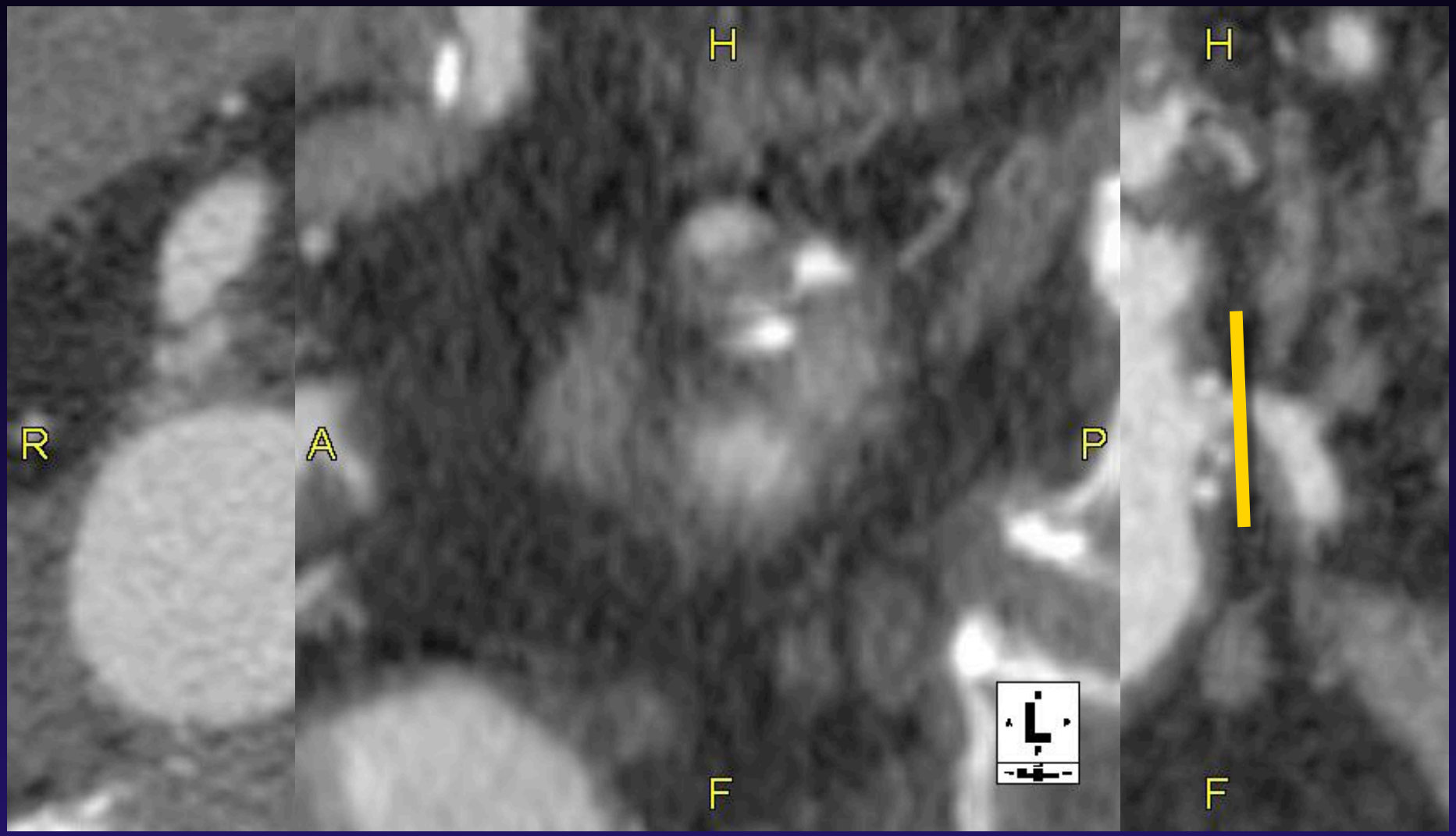

Curved Planar Reformation (CPR)

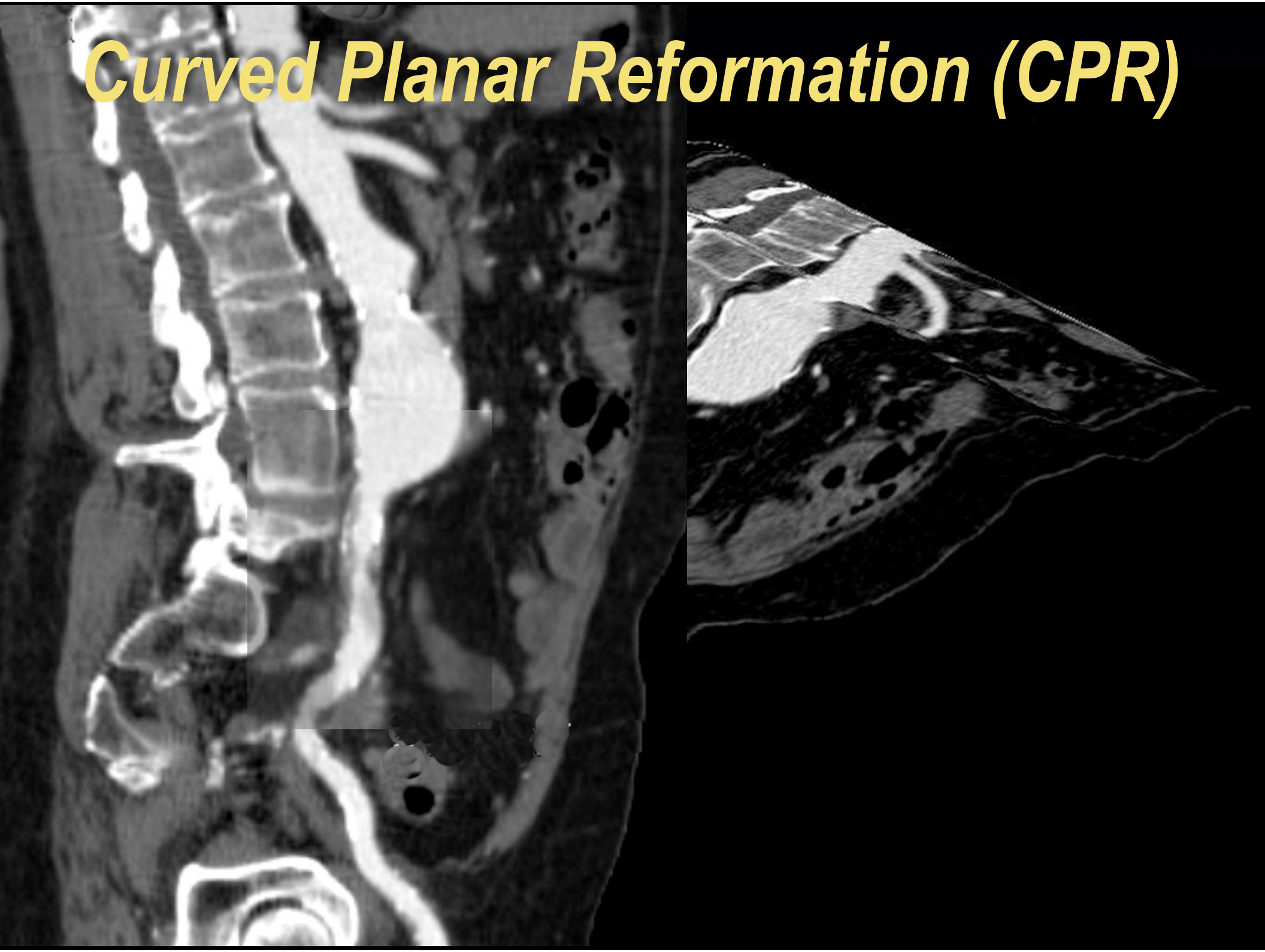

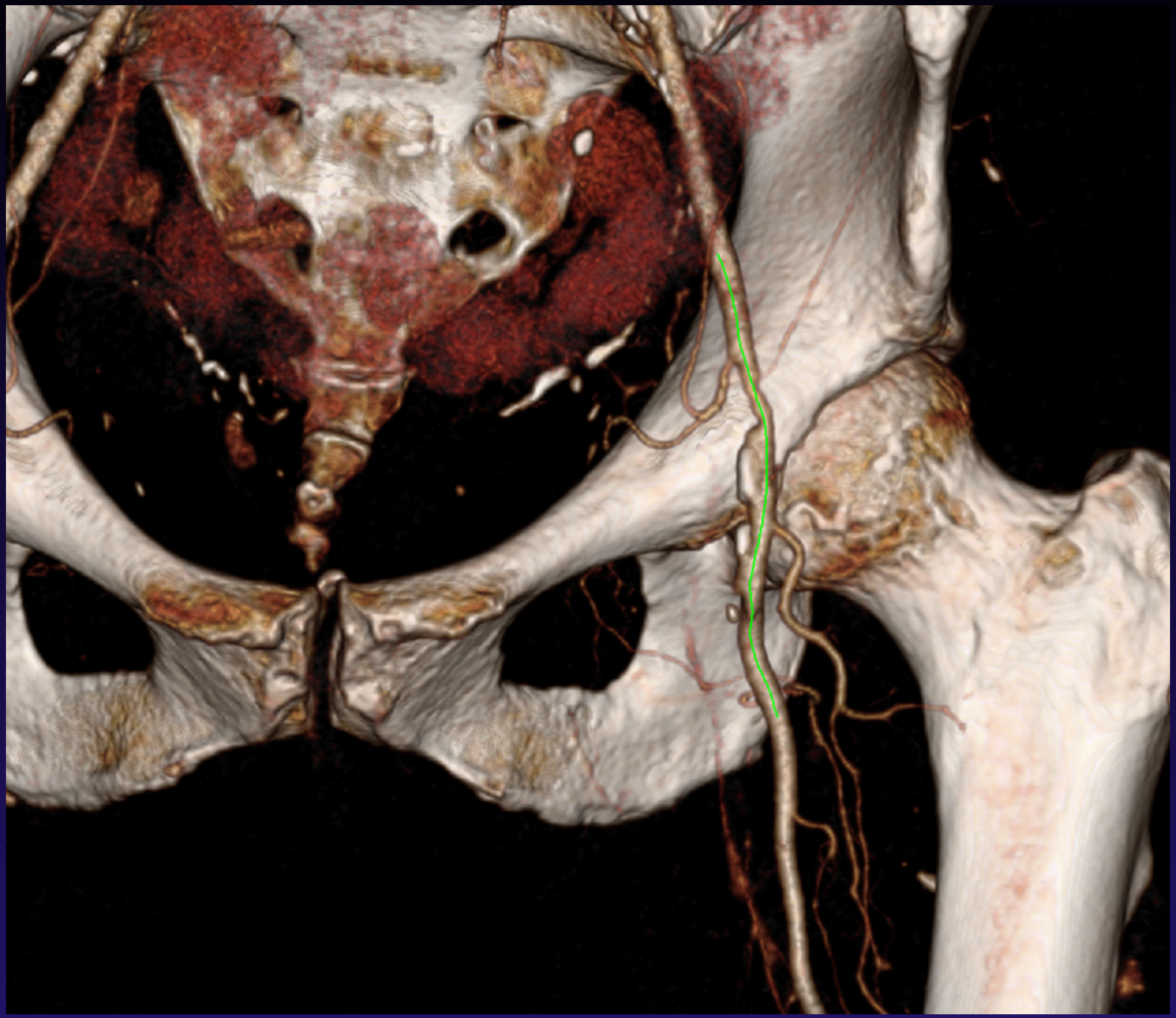

SFA Stents

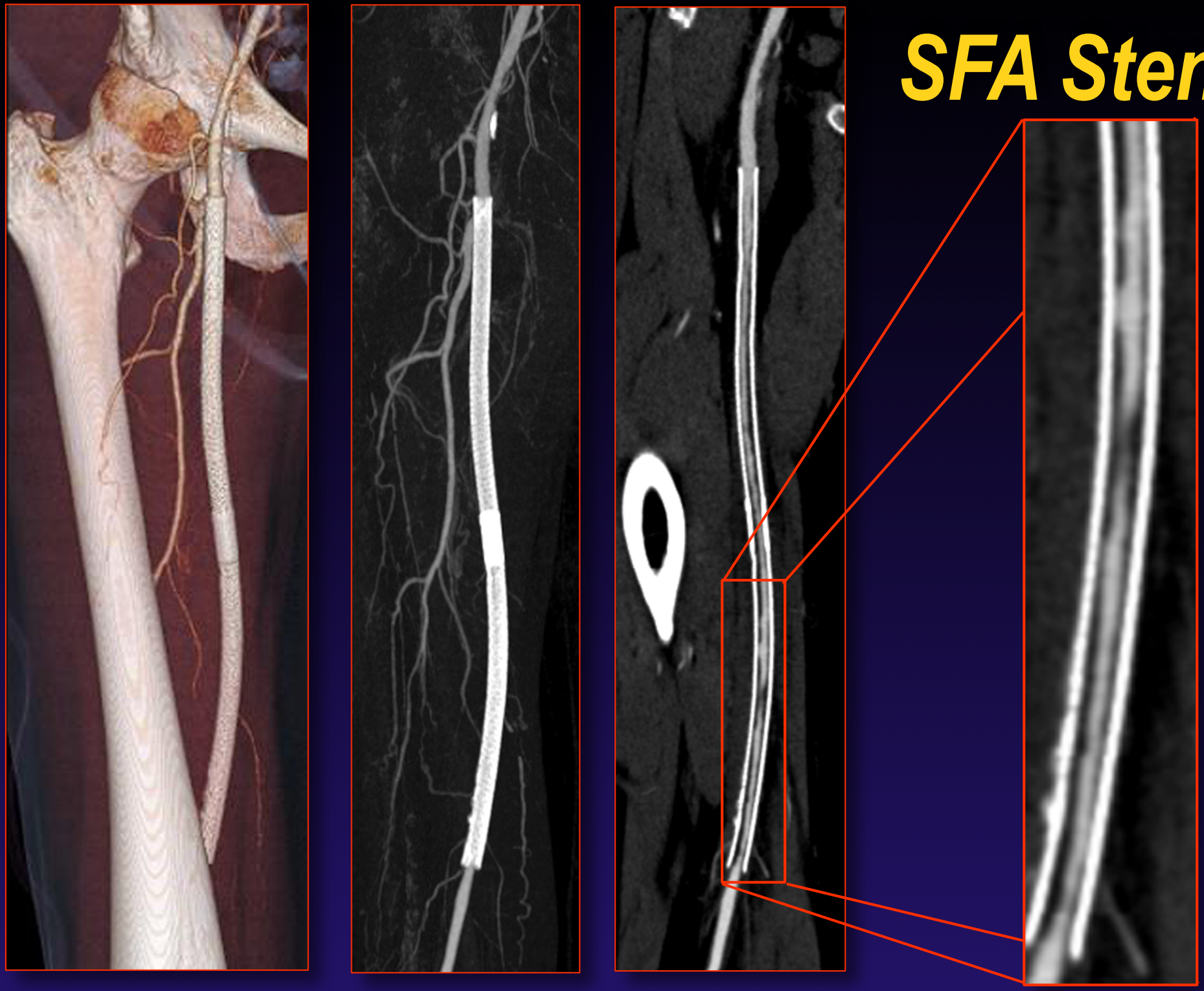

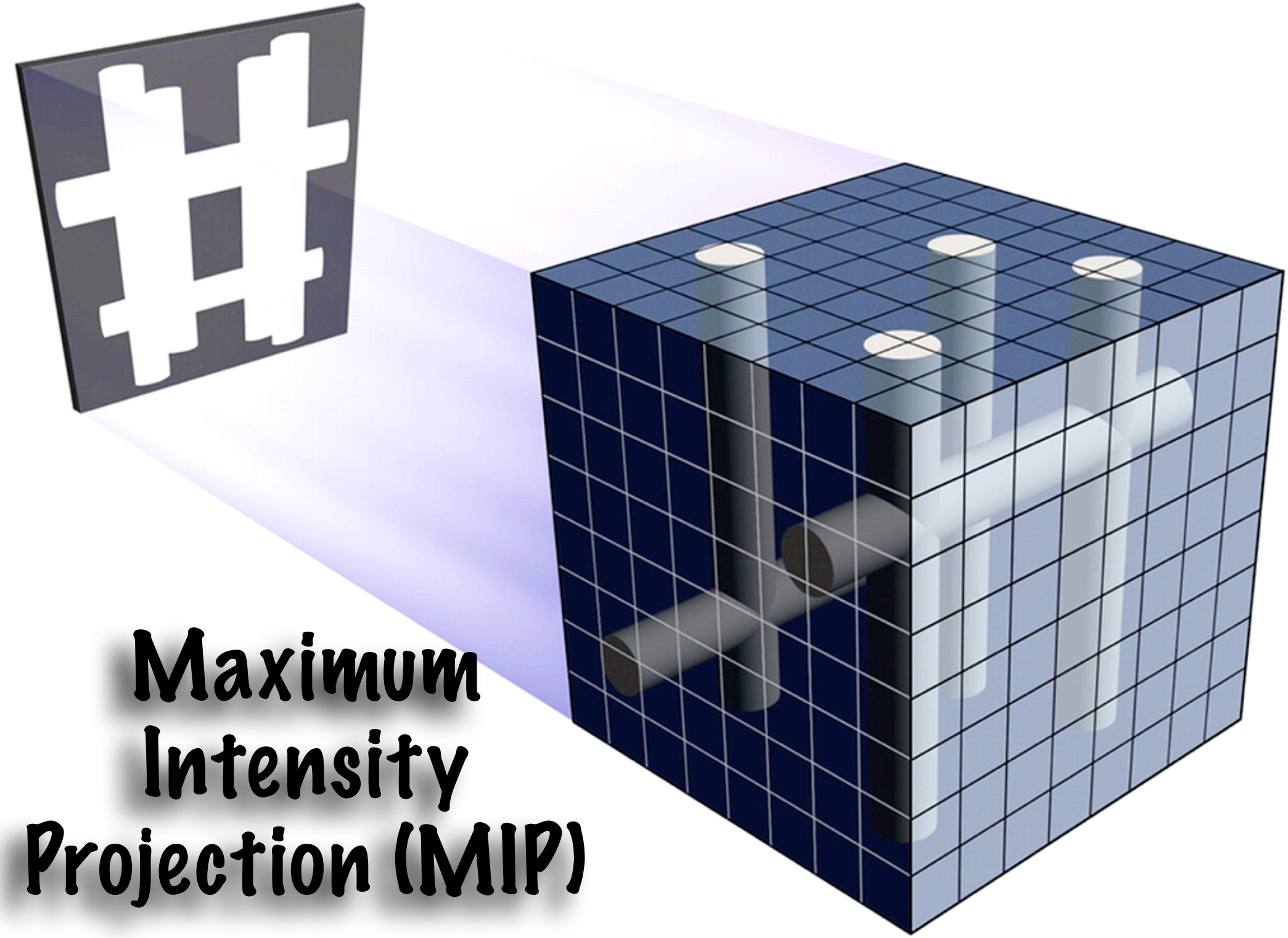
Maximum
Intensity
Projection (MIP)

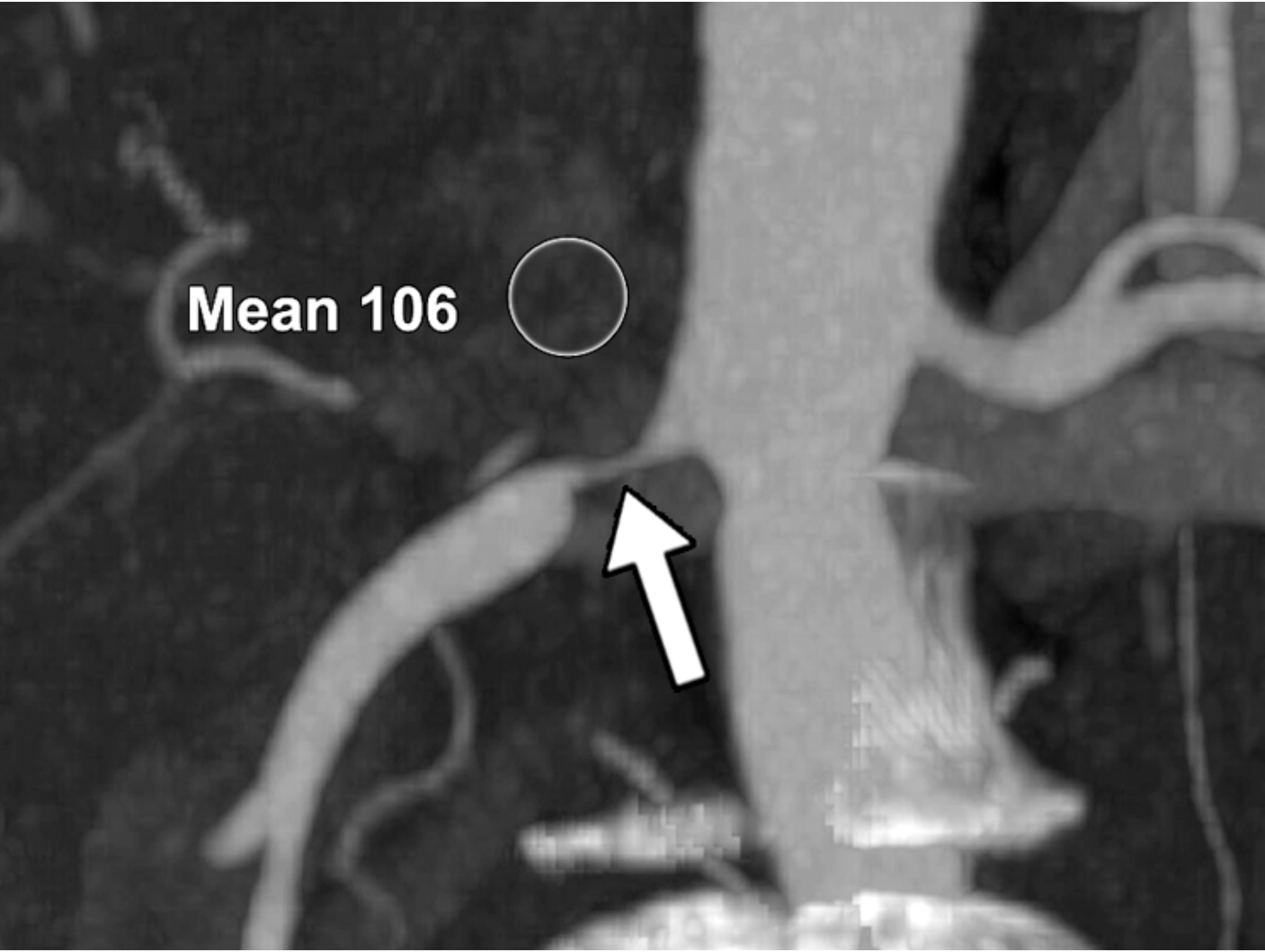
Mean 106

Aortic Stenosis

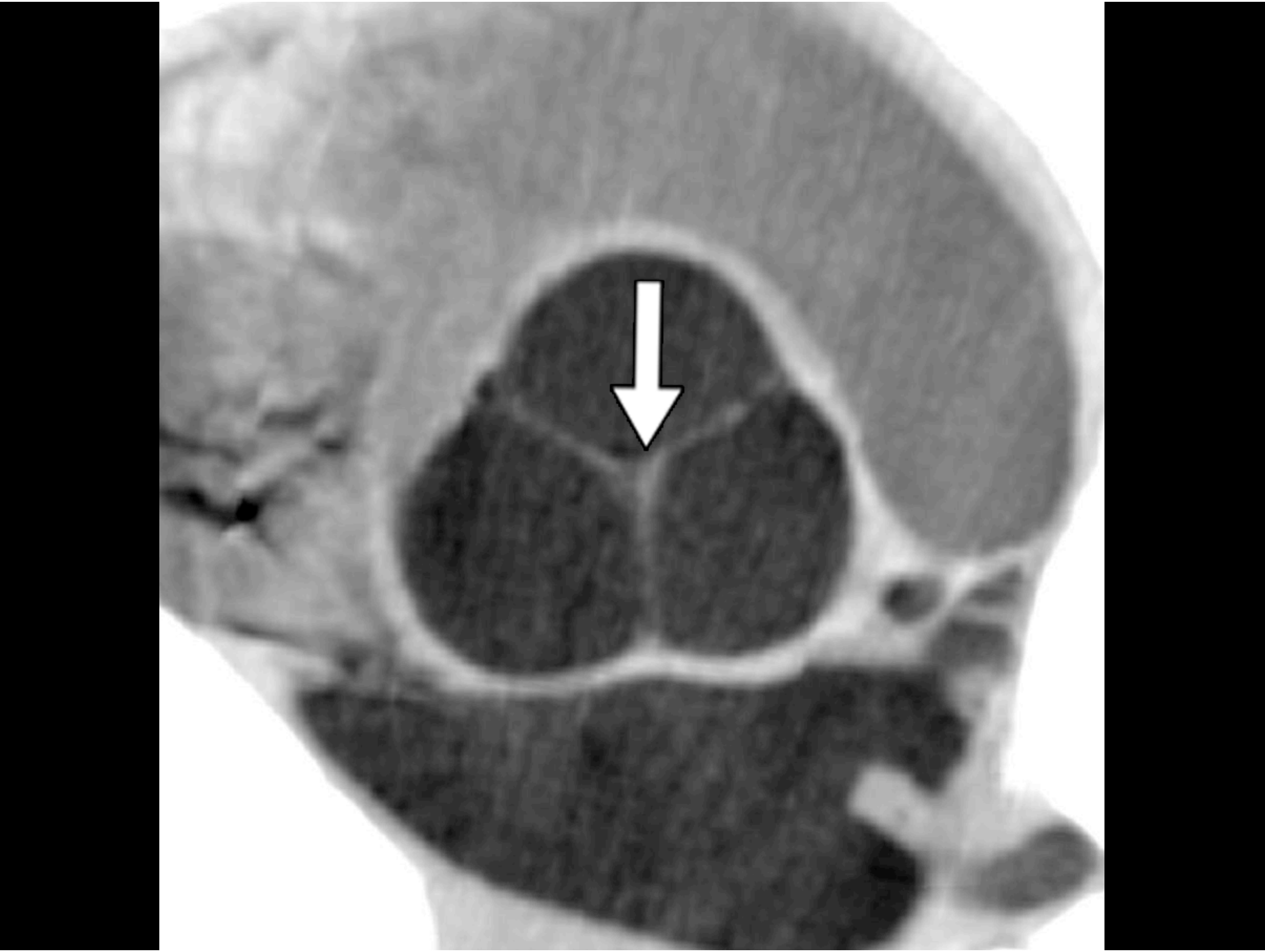

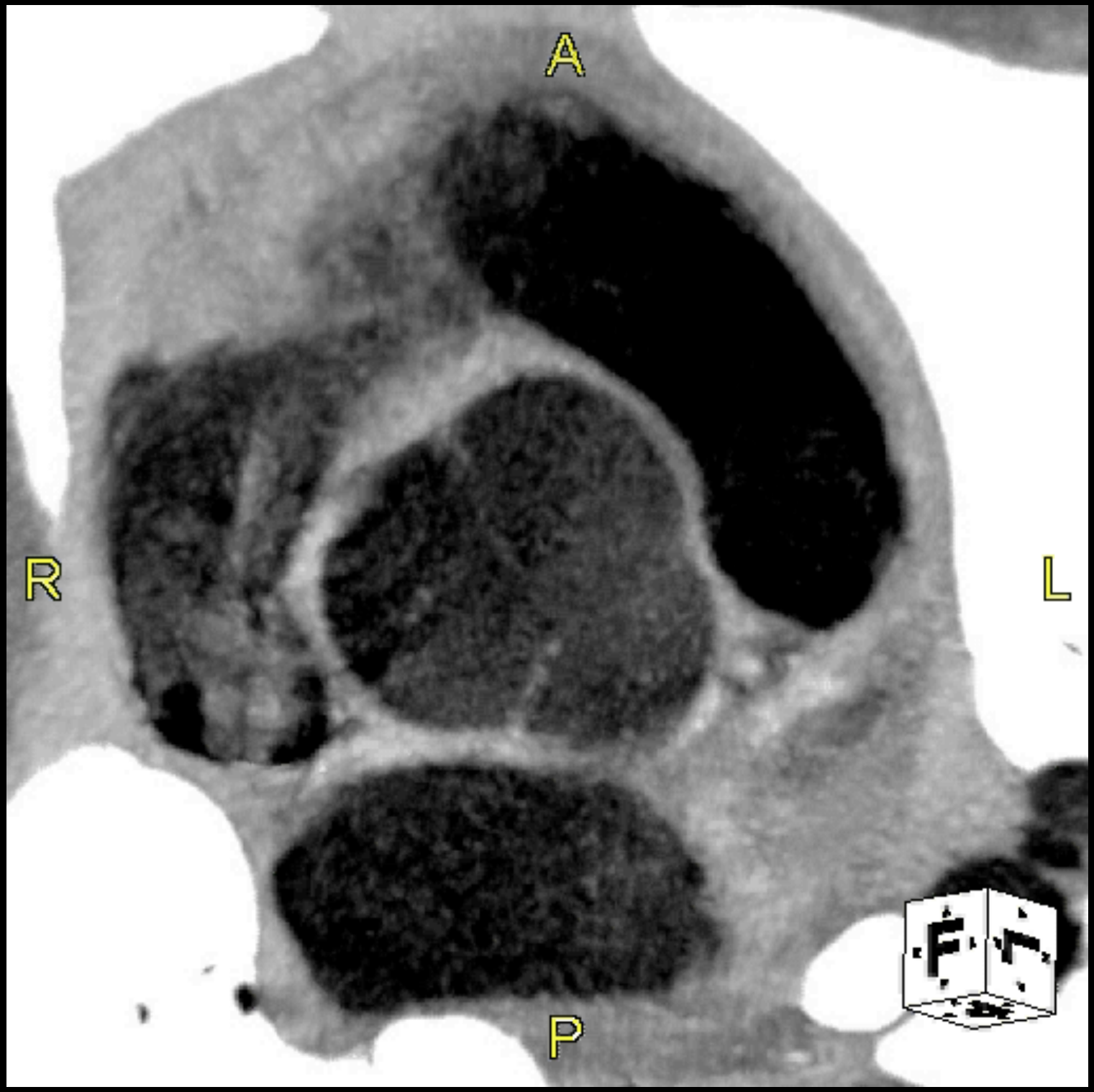
A
R
L
P

Volume Rendering

Opacity Transfer Function

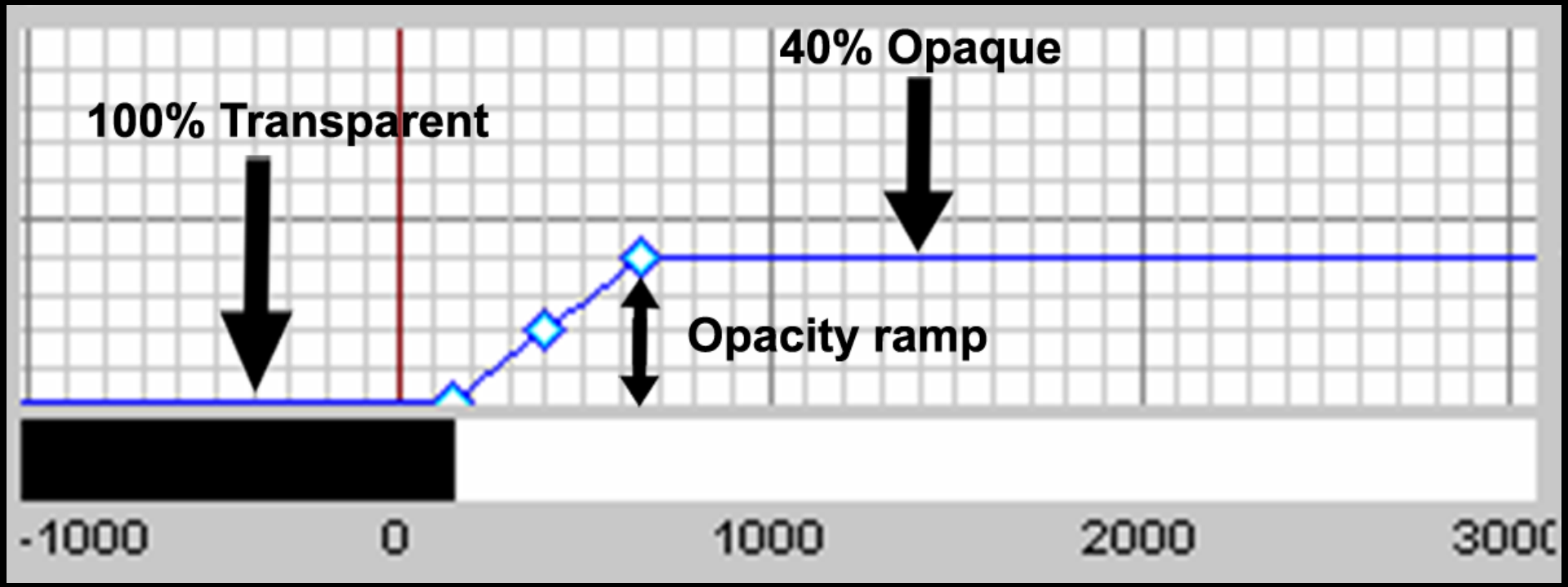

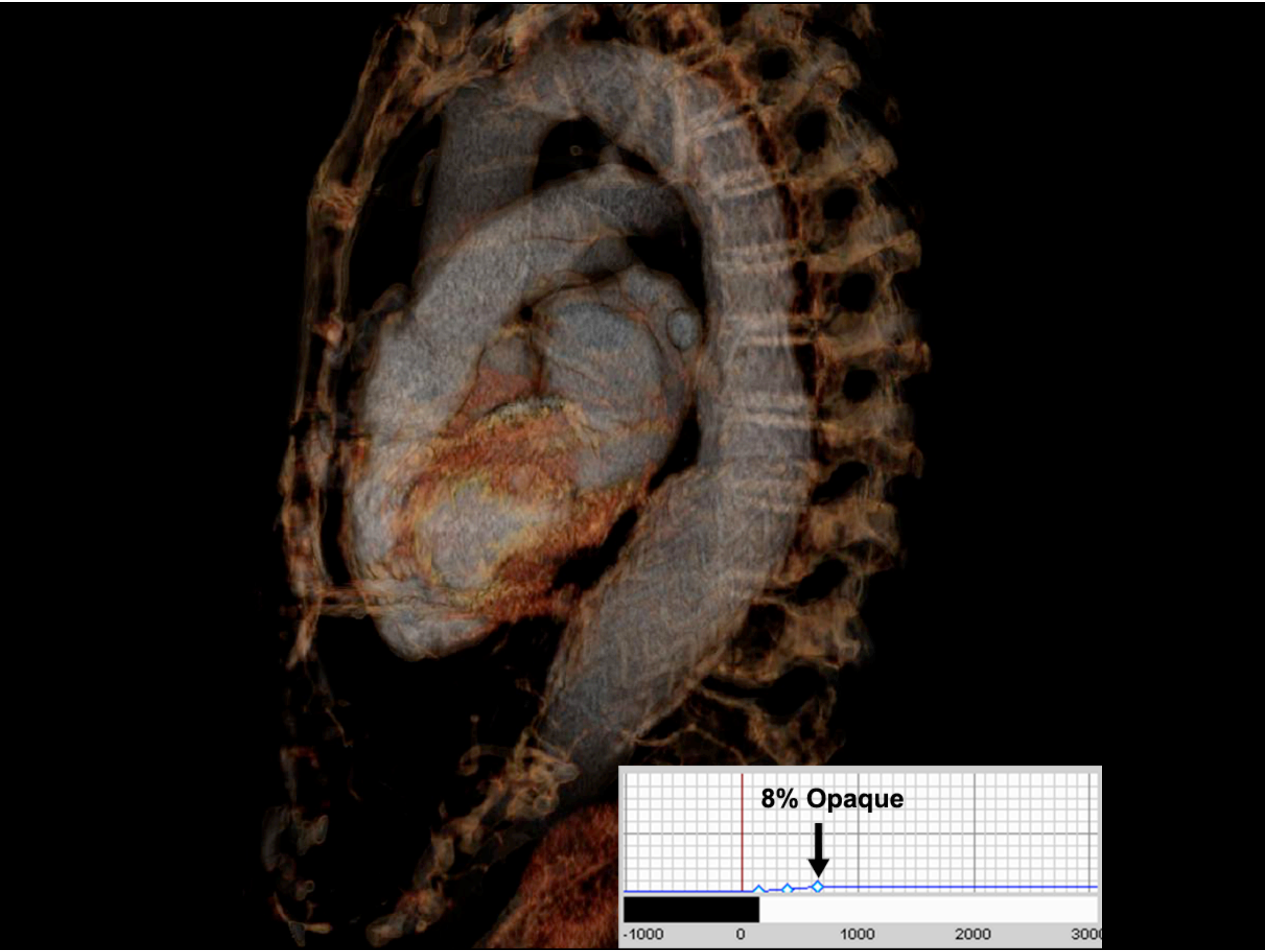
8% Opaque
-1000
0
1000
2000
3000

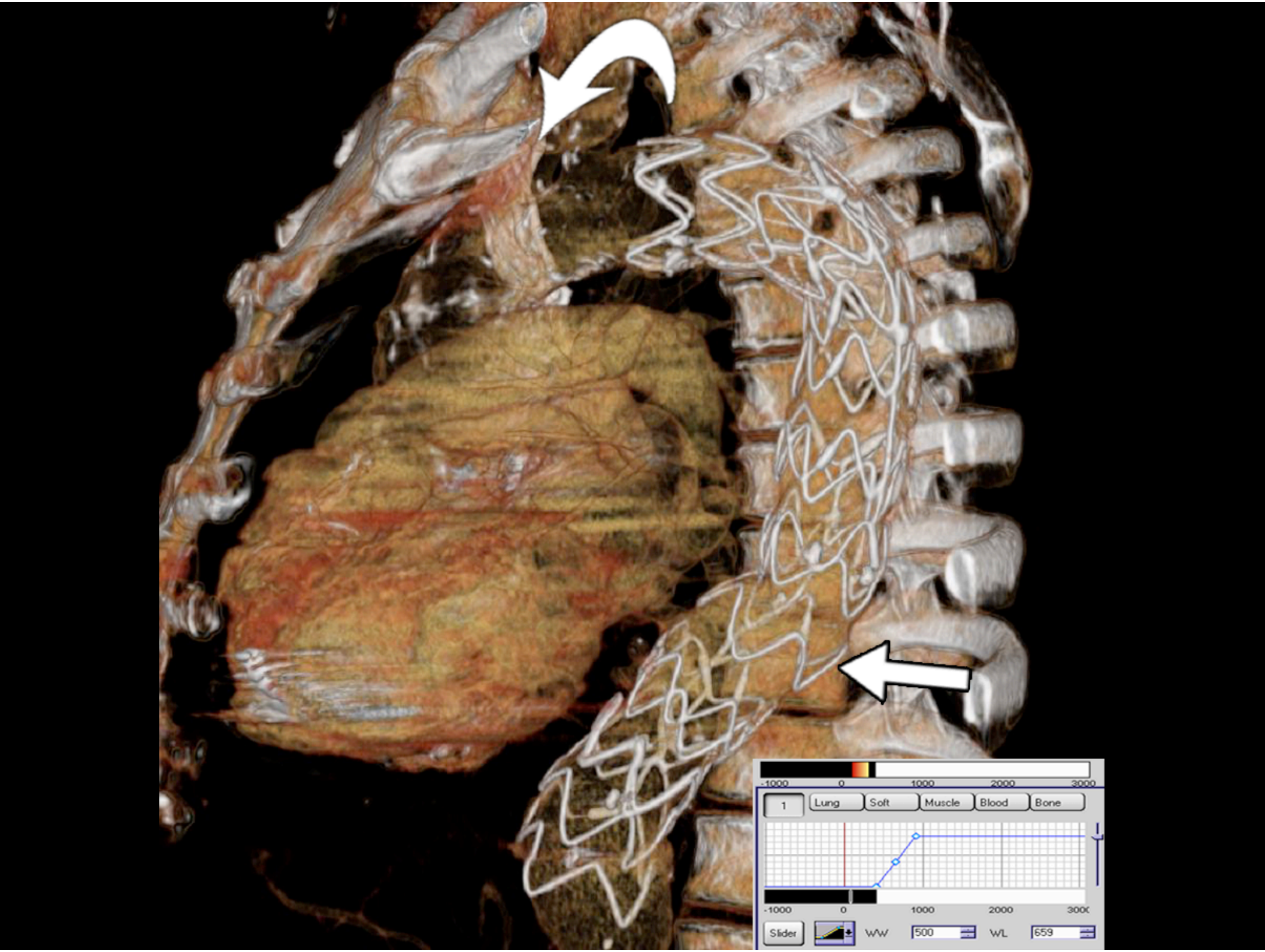
-1000
0
1000
2000
3000
1
Lung
Soft
Muscle
Blood
Bone
-1000
0
1000
2000
3000
Slider
WW
500
WL
659

Projectional Radiography

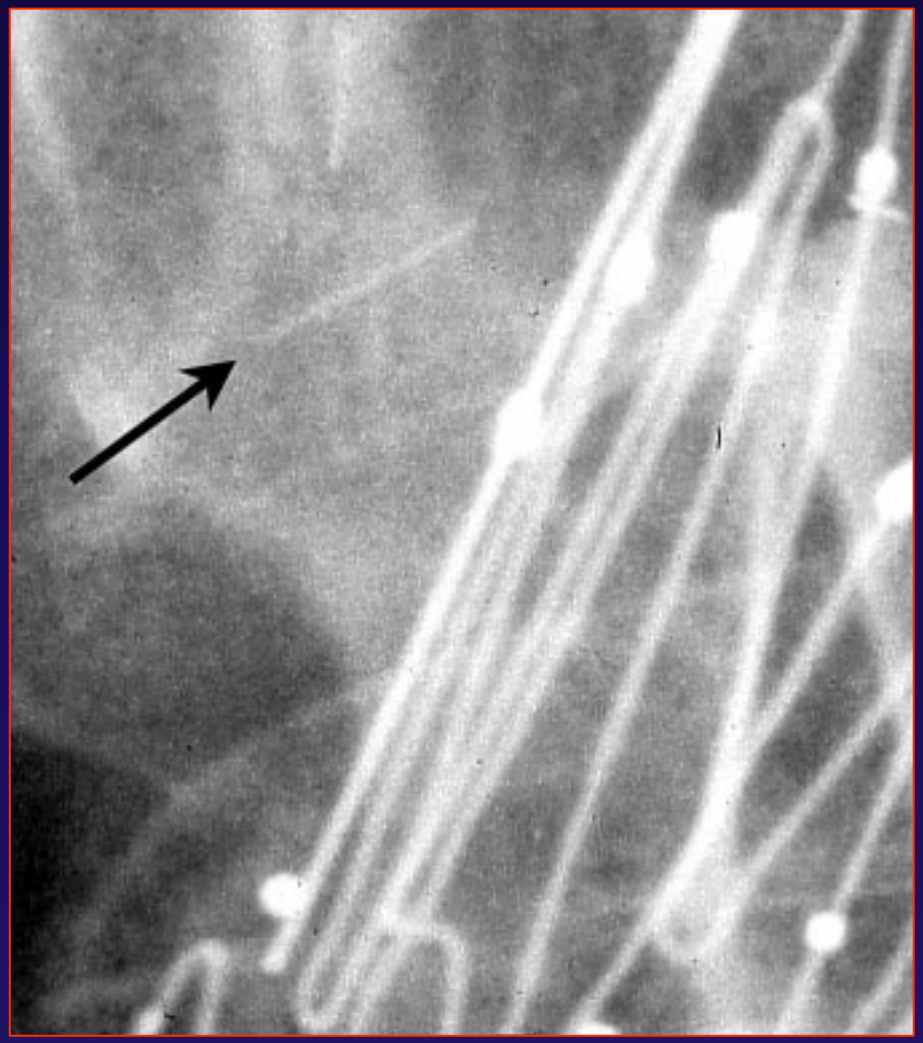

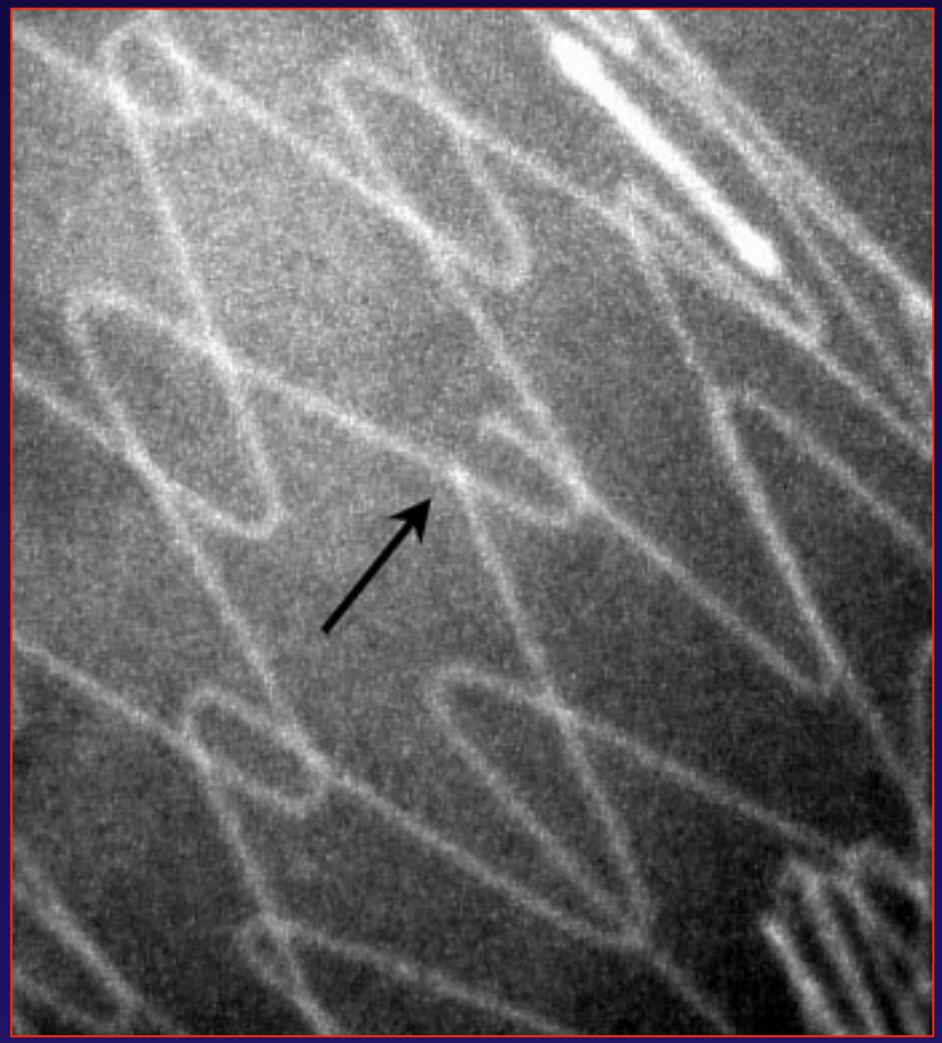

J ENDOVASC THER
2003;10:911–912

◆ TECHNICAL NOTE ◆

Plain Radiographic Surveillance of Abdominal Aortic Stent-Grafts: The Liverpool/Perth Protocol

Micheal Murphy, FRCSI, FRCR[1]; Richard Hodgson, PhD[3]; Peter L. Harris, MD, FRCS[2]; Richard G. McWilliams, FRCS, FRCR[1]; David E. Hartley, FIR[4]; and Michael M.D. Lawrence-Brown, FRACS[4]

Departments of [1]Interventional Radiology and [2]Vascular Surgery, Royal Liverpool University Hospital, and [3]Department of Medical Imaging, University of Liverpool, England, UK. [4]Department of Vascular Surgery, Royal Perth Hospital, Perth, Western Australia

Radiography Challenges

- Overpenetration
- Underpenetration
- Scatter
- Motion
- Overlap with other device components
- Overlap with body tissues
- Landmarks

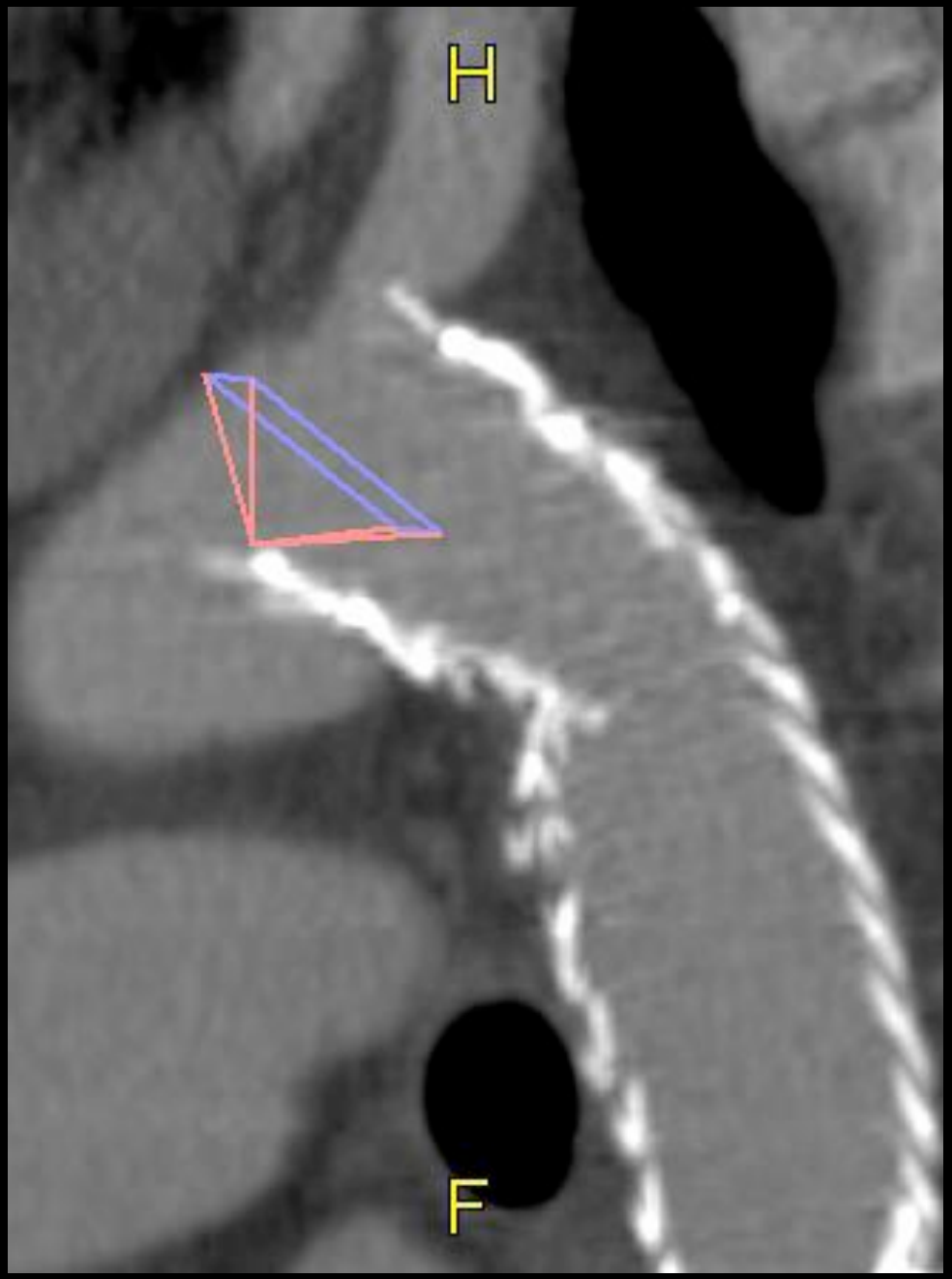
H
F

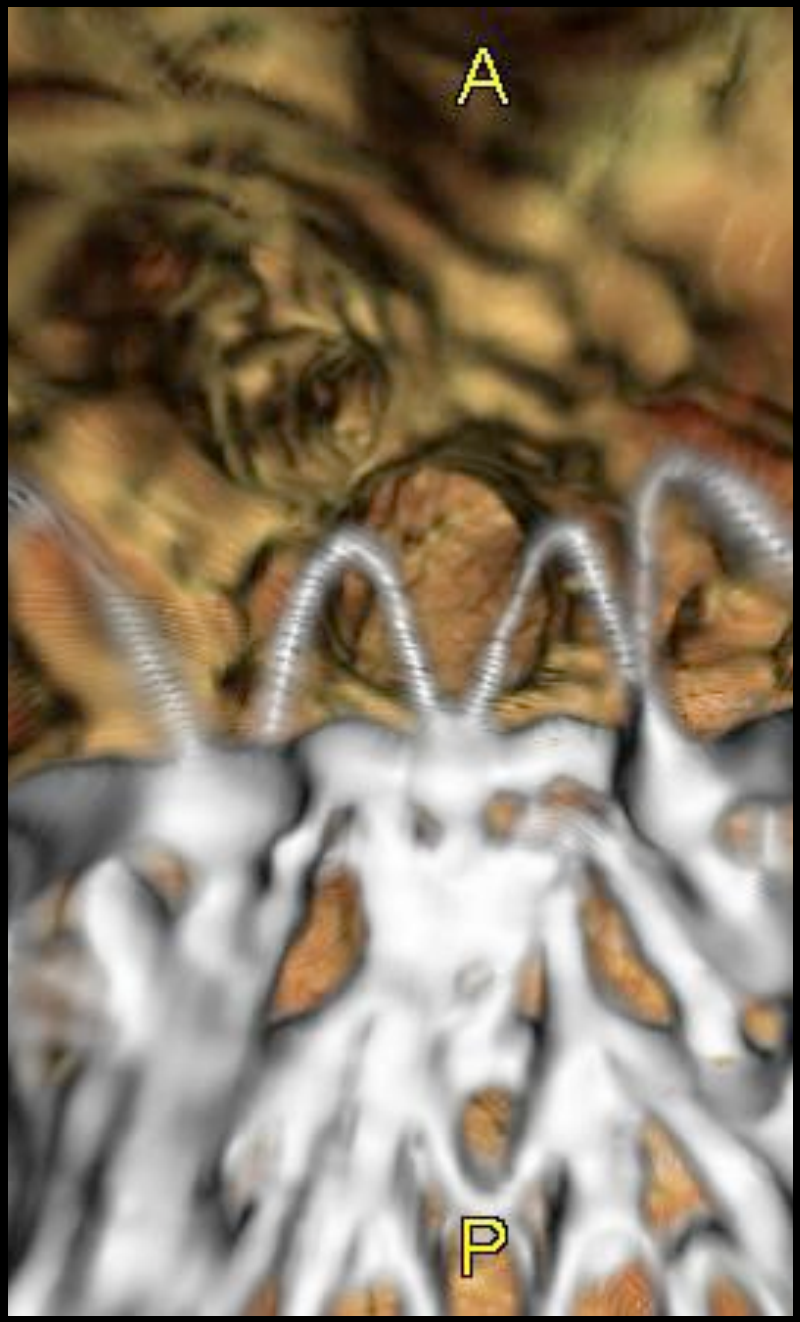
A
P

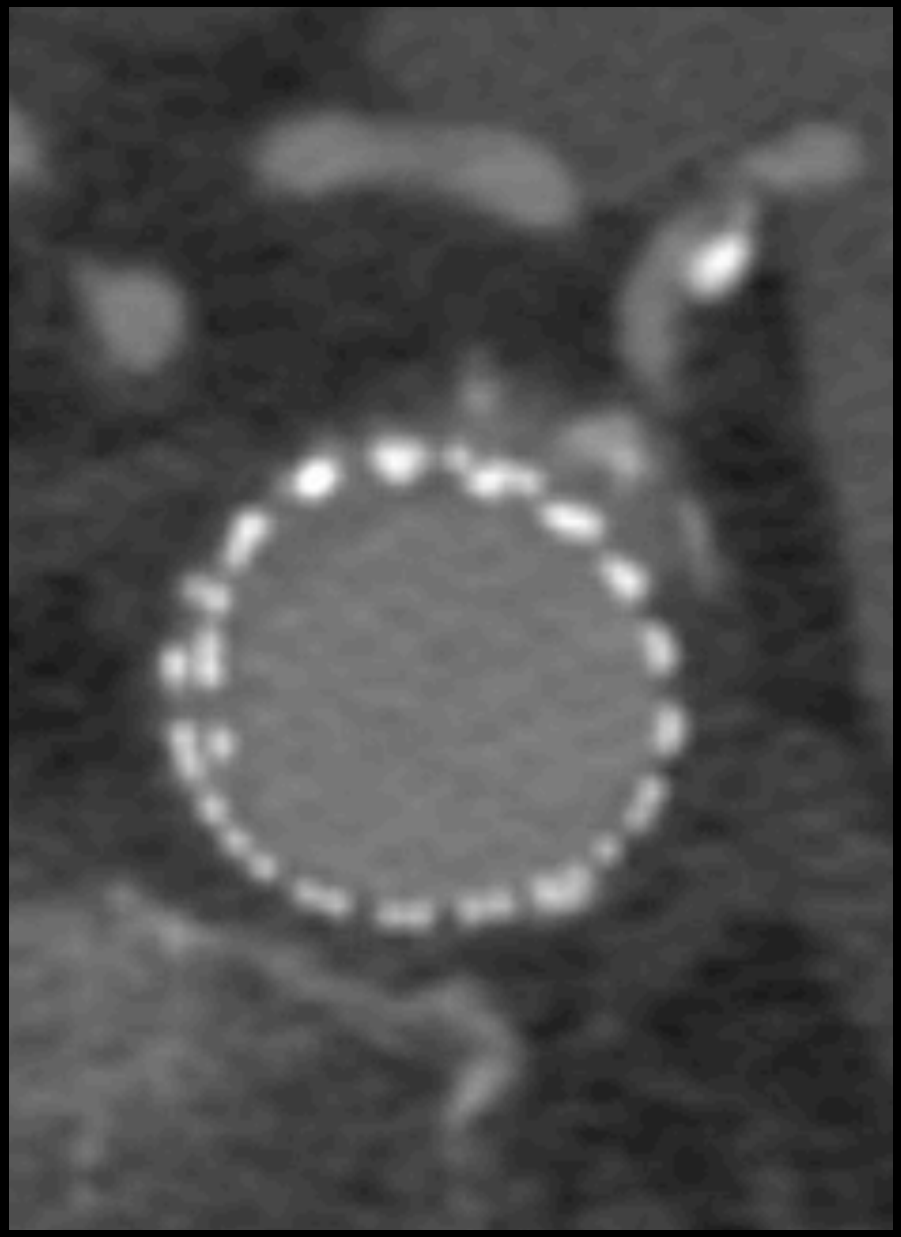

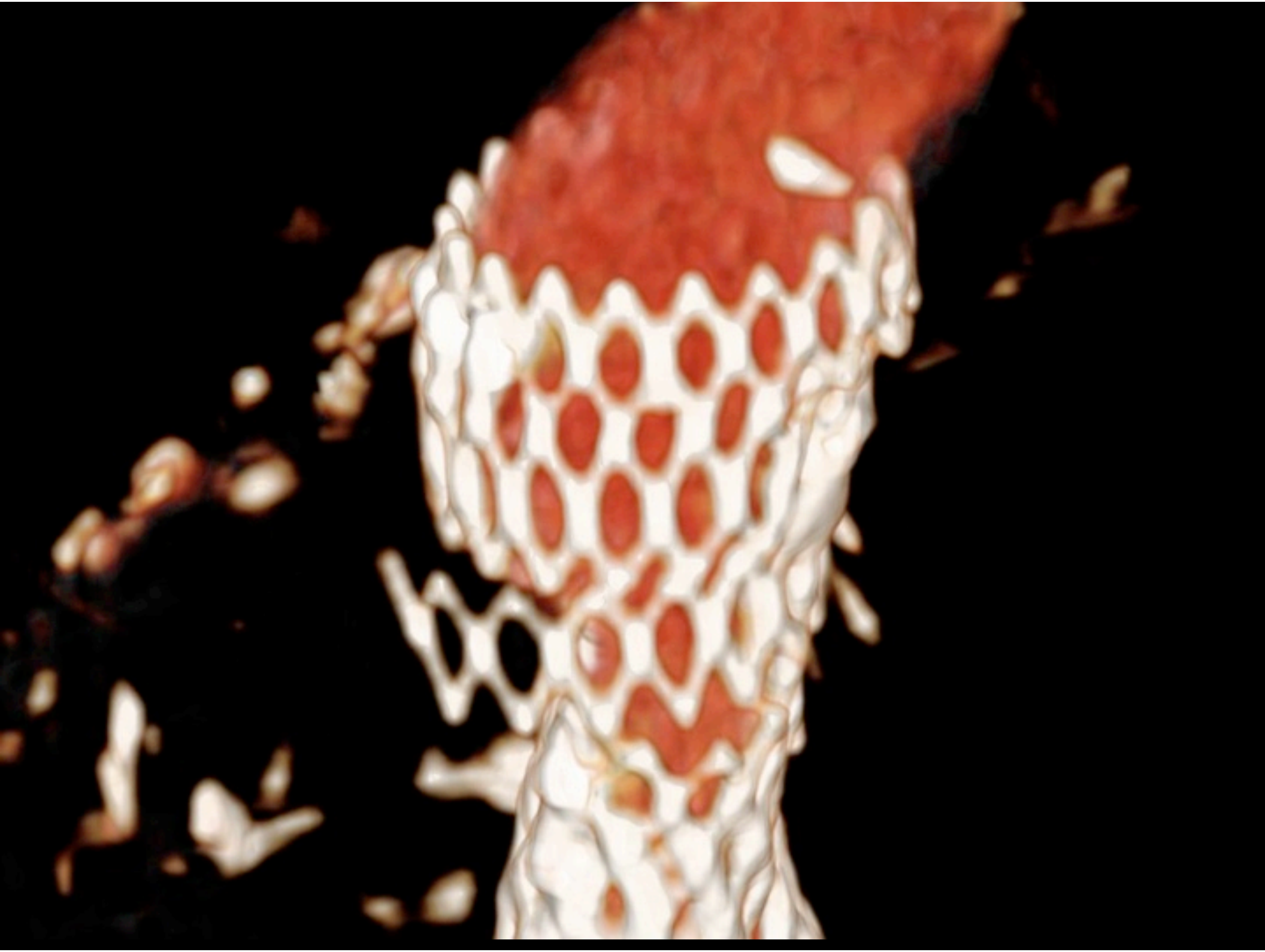

25 month interval


Length: 6.28mm


Length: 15.96mm


Length: 1.52mm


Length: 12.81mm

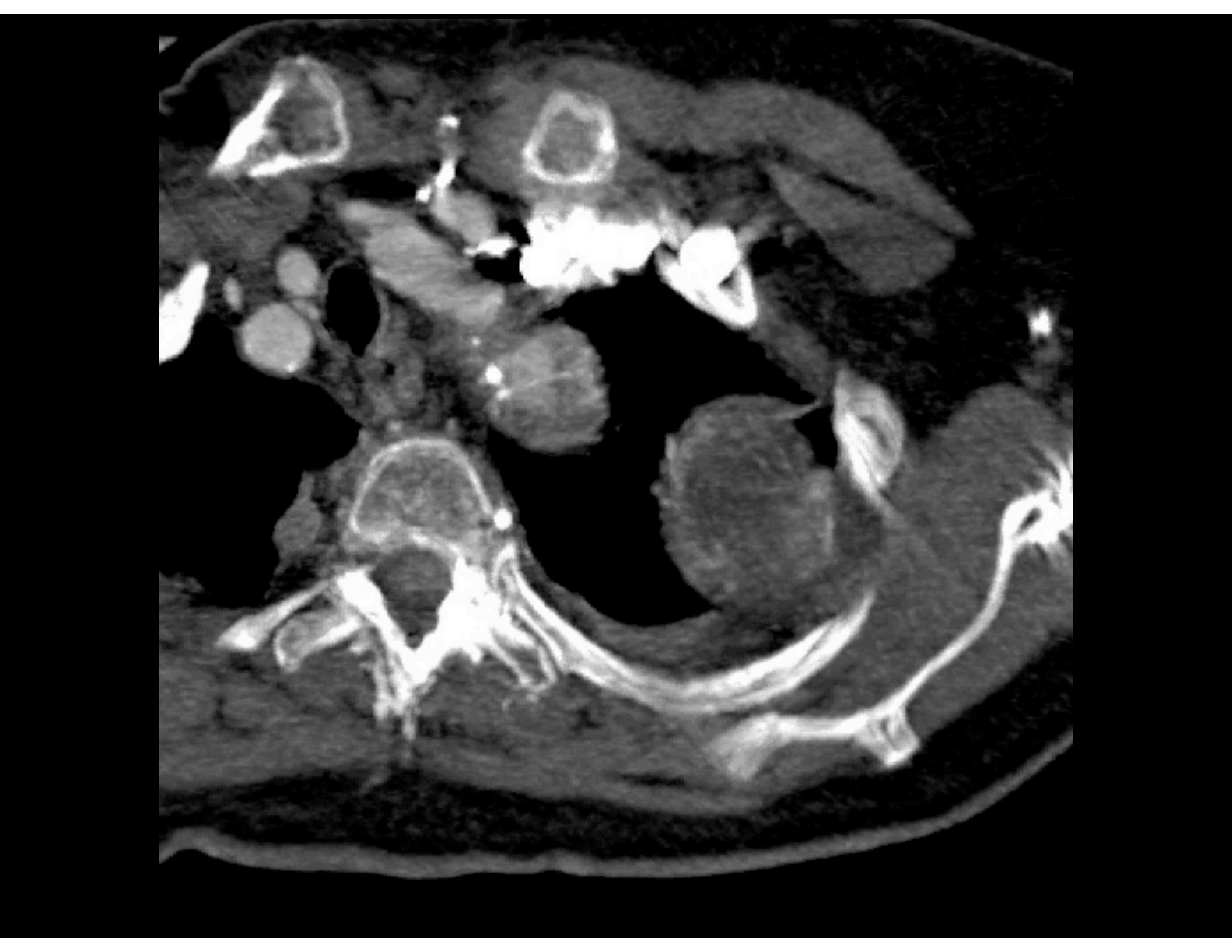

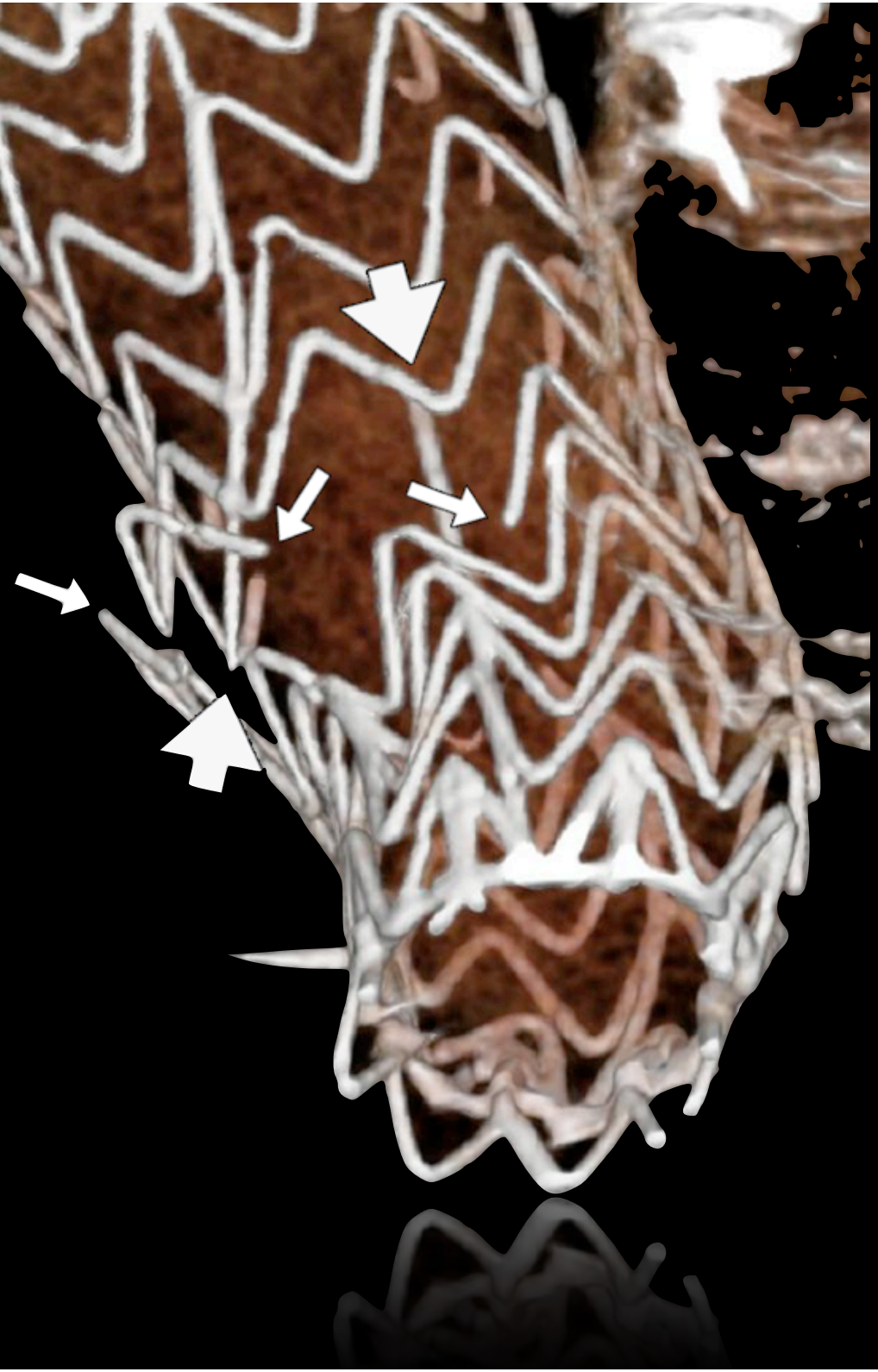


A
T
T

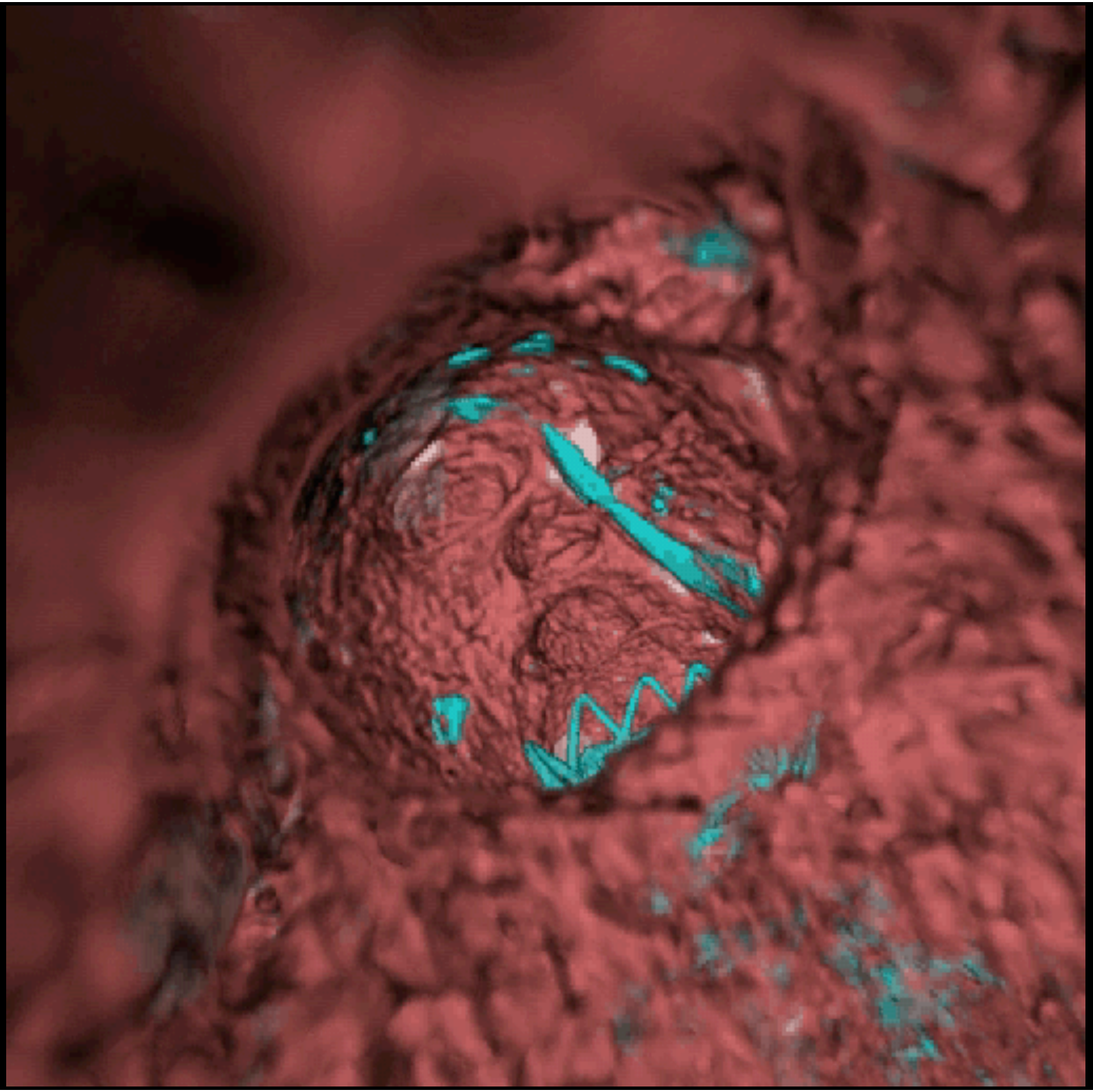

Summary

- Inherently volumetric data are best interpreted volumetrically
  - Device and procedure selection
- Informing management fully necessitates:
  - Training of surgeons, radiologists, technologists
  - Protocols for visualization and analysis
  - Refined endpoints